

Introduction

It is important to note that Crohn's associated malignancies are often difficult to detect. The mechanism widely accepted as the cause of intestinal cancers in Crohn's disease is long standing inflammation, though the association between Crohn's and gastric malignancies remains controversial due to a the scarcity of cases of coinciding gastric Crohn's and gastric malignancy. The link between gastric adenocarcinoma and Crohn's disease is unclear, due the fact that most Crohn's patients with gastric cancer have never had detected disease in the stomach. This may be why there has as of yet been no clear evidence that Crohn's disease in and of itself increases the risk of gastric cancer, but it remains unclear if gastric Crohn's disease can increase that risk.

Case Description

We report a patient with long-standing history of Crohn's disease, with gastric involvement, who developed adenocarcinoma of the gastric outlet. Our patient is a 62-year-old female with a long standing history of Crohn's disease who was being treated with adalimumab. She had an upper endoscopy at an outside institution four months prior to presentation for a history of abdominal discomfort which revealed friable gastric antral mucosa. Active Crohn's gastritis was noted on pathology at that time, but no evidence of malignancy. She presented to our institution with complaints of nausea, vomiting, and weight loss.

Endoscopic Evaluation

An upper endoscopy was performed revealing granular looking mucosa with ulceration causing severe stricture of the pylorus (Figure 1). Examination of the remainder of the stomach showed polyps in the gastric fundus (Figure 2). A guidewire was passed through the pyloric channel under fluoroscopy and the scope was advanced into the duodenal bulb. The mass was noted to be invading the pyloric channel, ending at the duodenal bulb, total length 19.2 mm. Echoendoscopic evaluation revealed the mass to have circumferential involvement of the pyloric channel with a n average depth of 12.2mm. involving the mucosa, submucosa and in the most thickened area of the wall, was seen extending slightly beyond the muscularis propria

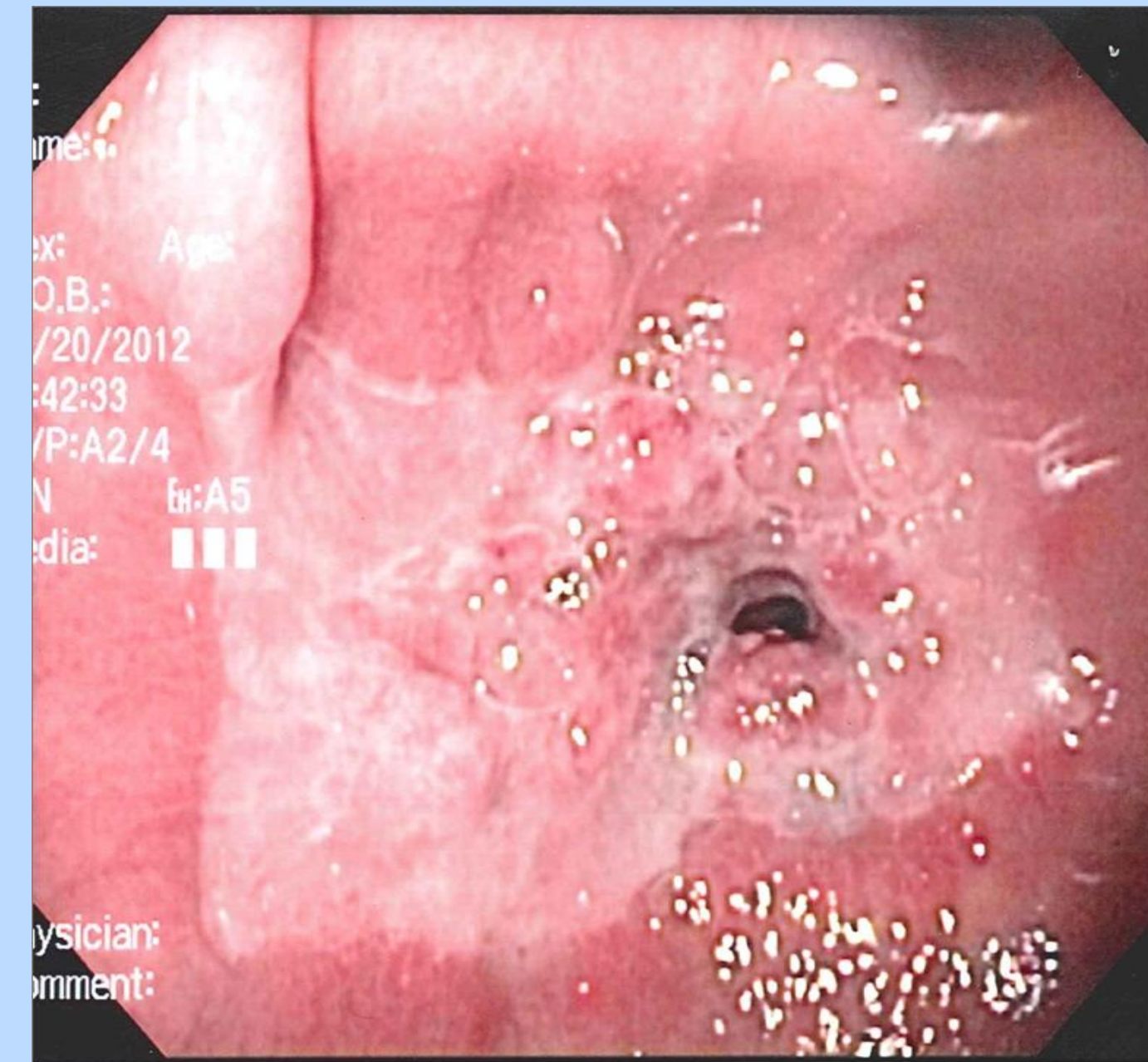


Figure 1. Gastric Outlet with high degree stricture due to mass

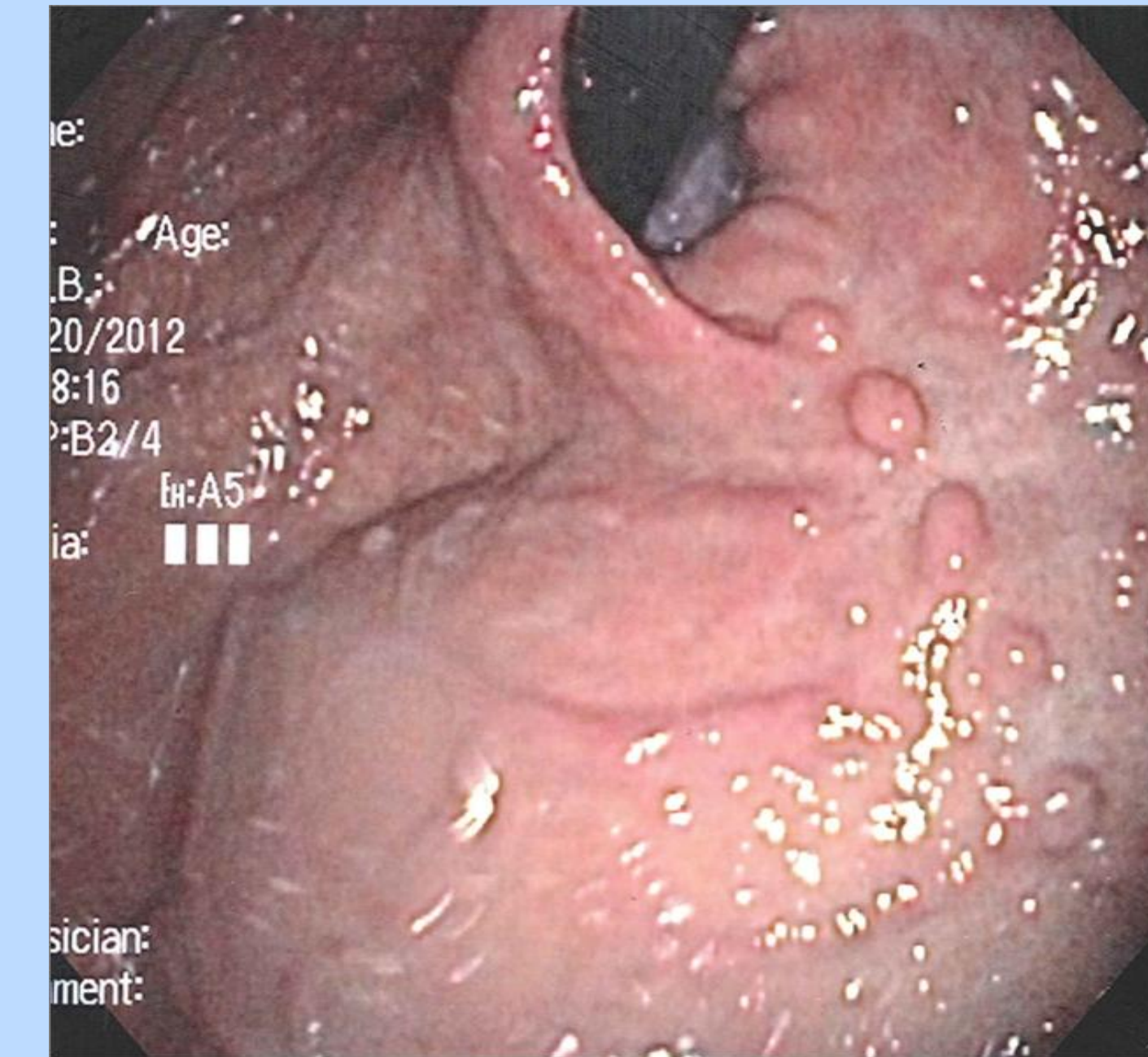


Figure 2: Multiple gastric polyps in the fundus

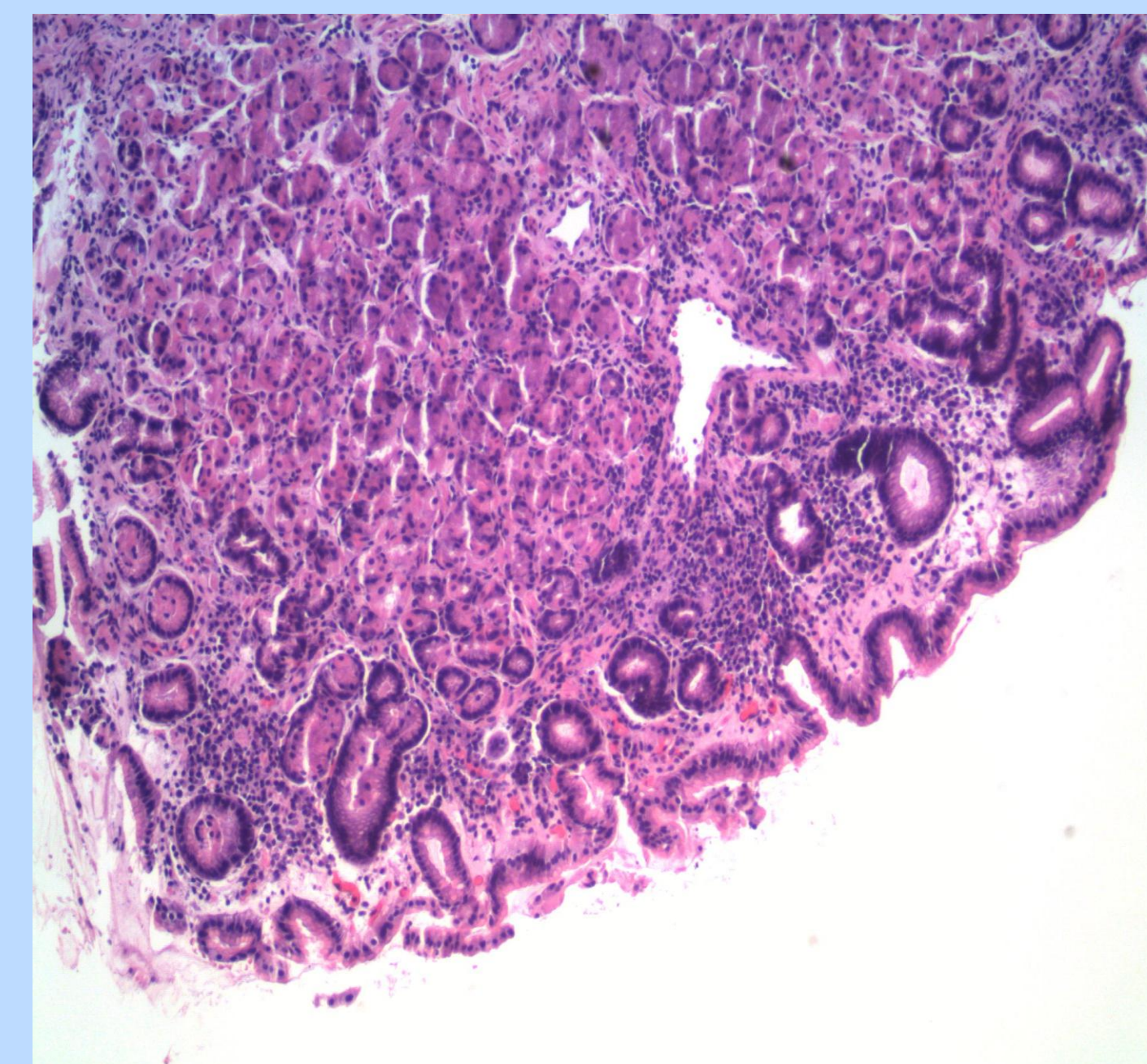


Figure 3: Normal Gastric mucosa obtain from biopsy of gastric fundus polyps

Biopsy Results and Surgery

Biopsies of the polyps revealed mild active gastritis with surrounding normal gastric mucosa, questionable for pseudopolyps (Figure 3). Biopsies of the pylorus revealed poorly differentiated adenocarcinoma with signet cells. The patient was referred to surgery for subtotal gastrectomy. Surgery was done at an outside institution and revealed adenocarcinoma of the pyloric channel without extension into the surrounding lymph nodes or organs.

Conclusion

It appears that malignancies may have a higher mortality rate in Crohn's disease patients than those seen in ulcerative colitis (82% vs. 50% 5yr mortality in one study), due to the difficulty in diagnosis in patients with Crohn's disease. Adenocarcinoma of the gastric outlet can develop in a patient with long standing history of Crohn's disease of the stomach. Aggressive biopsies might be necessary to differentiate between infiltrative adenocarcinoma and active Crohn's gastritis. Greater detection of gastric Crohn's may lead to better screening for gastric adenocarcinoma in this population and shed greater light on any possible link between gastric Crohn's disease as adenocarcinoma of the stomach.

References

1. Patel M, Banerjee B, Block JG, et al. Gastric Crohn's disease complicated by adenocarcinoma of the stomach: case report and review of the literature. *Am J Gastroenterol* 1997;92:1368–71.
2. Ikeuchi H, Kusunoki M, et al. Crohn's disease associated with gastric cancer. *J Gastroenterol* 2002; 34: 47-49
3. Greenstein AJ, Sachar DB, Smith H, et al. Patterns of neoplasia in Crohn's disease and ulcerative colitis. *Cancer* 1980;46:403–7.