

# Synchronous EUS-guided choledochoduodenostomy with metallic biliary and duodenal stents placement in a patient with malignant papillary tumor

Raja V. Thotakura, Sreekiran Thotakura, Aijaz Sofi, Muhammad Z. Bawany, Ali Nawras

University of Toledo Medical Center, Toledo OH, United States

**Key words:** EUS-Guided Choledochoduodenostomy (EUS-CDS), failed ERCP, ampullary cancer, metallic stents, biliary obstruction, duodenal obstruction

**Abbreviations:** ERCP, endoscopic retrograde cholangiopancreatography; EUS, endoscopic ultrasound; CBD, common bile duct

## Introduction

Endoscopic retrograde cholangiopancreatography (ERCP) is the procedure of choice for biliary drainage in patients with biliary obstruction from multiple etiologies. When ERCP is unsuccessful, the traditional alternatives are percutaneous transhepatic biliary drainage or surgical decompression. We present a case of a malignant ampullary mass causing both biliary and duodenal obstruction that was successfully treated with simultaneous endoscopic ultrasound (EUS) guided choledochoduodenostomy with metallic biliary and duodenal stents placement.

## Case profile

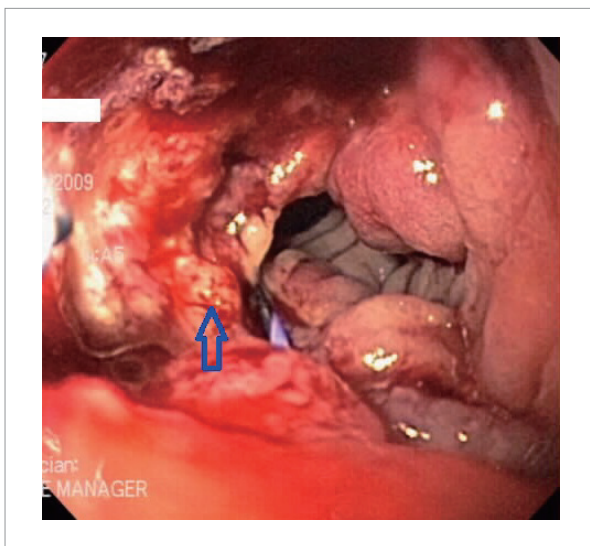
An 84-year old Caucasian lady with history of malaise, abdominal fullness, weight loss, abnormal LFTs and biliary obstruction was referred to our facility for an ERCP. She was previously diagnosed with ampullary adenocarcinoma with tumor invasion into the head of the pancreas. As the patient was deemed to be at high surgical risk due to significant comorbidities, a wide local excision of the ampulla of Vater including a portion of head of the pancreas followed by a sphincteroplasty was performed. She subsequently underwent adjuvant chemo and radiation therapy due to the pancreatic head involvement by the tumor. An attempted ERCP failed to cannulate the common bile duct (CBD) due to a large, infiltrative, ulcerated and circumferential mass involving the ampullectomy site and partially obstructing the second part of the duodenum (**Fig. 1**). An EUS showed dilation of the extra-hepatic bile duct associated with severe stenosis of the distal CBD (**Fig. 2**). Using the therapeutic linear echoendoscope (GFUCT160, Olympus, Tokyo, Japan), a 19 gauge FNA needle (Wilson-Cook Corporation, Winston-

Salem, North Carolina, USA) was advanced through the wall of the duodenal bulb into the CBD and a cholangiogram was performed by injecting contrast through the needle. A 0.035 inch guide wire (Boston Scientific, Natick, Massachusetts, USA) was then introduced through the needle into the common bile duct and advanced up to the intra-hepatic biliary tree. The needle was then removed and the RX-44 sphincterotome (Boston Scientific, Natick, Massachusetts, USA) was advanced over the guide wire into the CBD to dilate the choledochoduodenal fistula tract. The choledochoduodenal fistula was then created after further dilating the fistula tract with a 6 mm dilating balloon (Boston Scientific, Natick, Massachusetts, USA) (**Fig. 3**). An expandable metallic fully covered biliary Wallstent I (8 mm in diameter and 60 mm in length, Boston Scientific, Natick, Massachusetts, USA) was placed within the fistula tract (**Fig. 4**). The partially obstructed second part of duodenum was traversed with the endoscope and insertion of the Wallstent I (Boston Scientific, Natick, Massachusetts, USA) uncovered enteric expandable endoprosthesis (22 mm in diameter and 90 mm in length) was accomplished (**Fig. 5, Fig. 6, Fig. 7**). The patient had no complications from the procedure. Subsequently, a preplanned EUS-guided celiac plexus neurolysis was performed to control the patient's chronic abdominal pain. The patient had no complaints related to biliary and duodenal obstructions for the following six months.

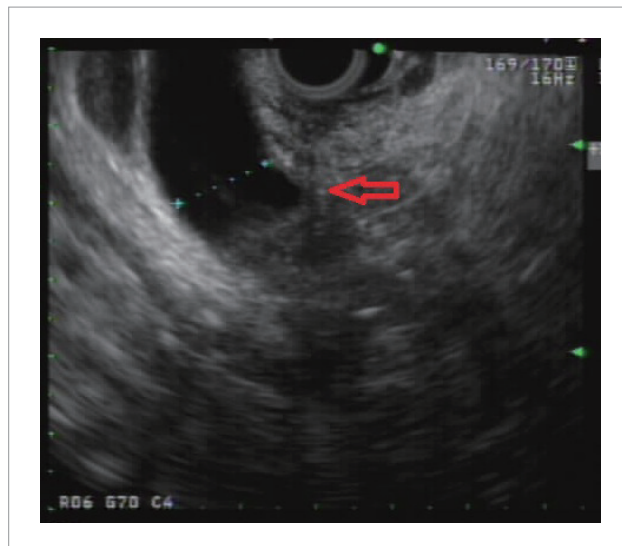
## Discussion

Ampullary cancers arise distal to the confluence of CBD and pancreatic ducts and usually present with jaundice secondary to distal CBD obstruction. ERCP is the procedure of choice for biliary cannulation and relief of obstruction via stent placement. Alternative therapies, that include percutaneous transhepatic drainage<sup>1</sup> and surgical bypass,<sup>2</sup> are associated with significant morbidity.<sup>3</sup> EUS guided extra hepatic biliary drainage via choledochoduodenostomy (EUS-CDS) has been reported in literature for biliary decompression in advanced pancreatic carcinomas in the context of a failed ERCP.<sup>4</sup> This method has

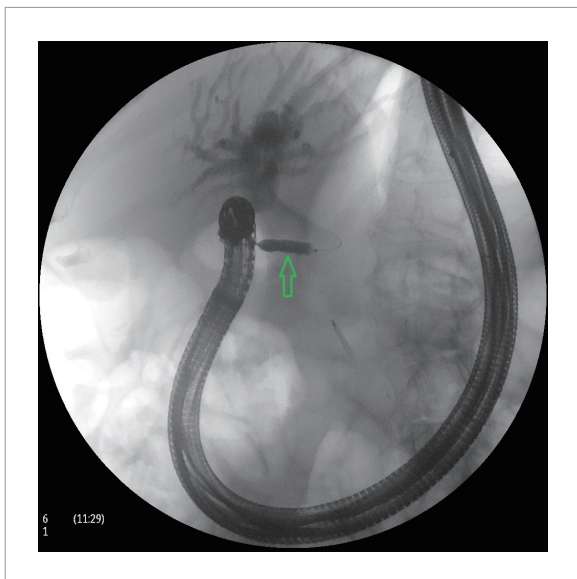
\*Correspondence to: Ali Nawras; Email: Ali.Nawras@utoledo.edu  
Submitted: Feb/27/2012; Revised: Apr/13/2012; Accepted: Apr/17/2012  
Previously published online: www.landesbioscience.com/journals/jig  
DOI: 10.4161/jig.22206



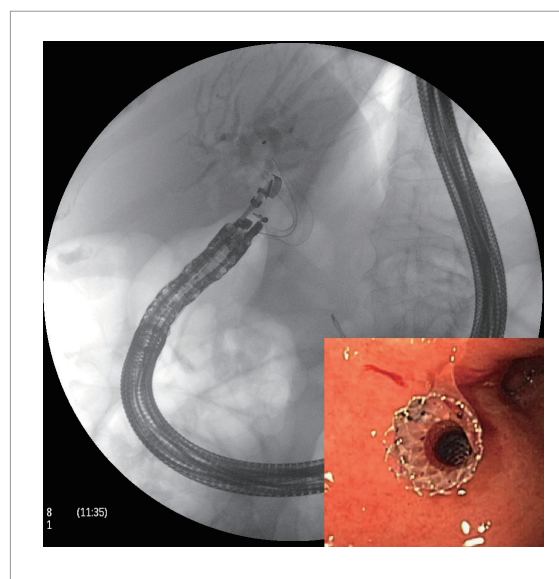
**Figure 1.** Recurrent infiltrative and ulcerated malignant mass in the second part of duodenum causing biliary and duodenal obstruction (arrow).



**Figure 2.** EUS showing dilated CBD (15 mm) with distal obstruction (arrow).



**Figure 3.** Fluoroscopic image showing balloon dilatation of choledochoduodenostomy tract with the guide wire located in the intra-hepatic bile ducts (arrow).

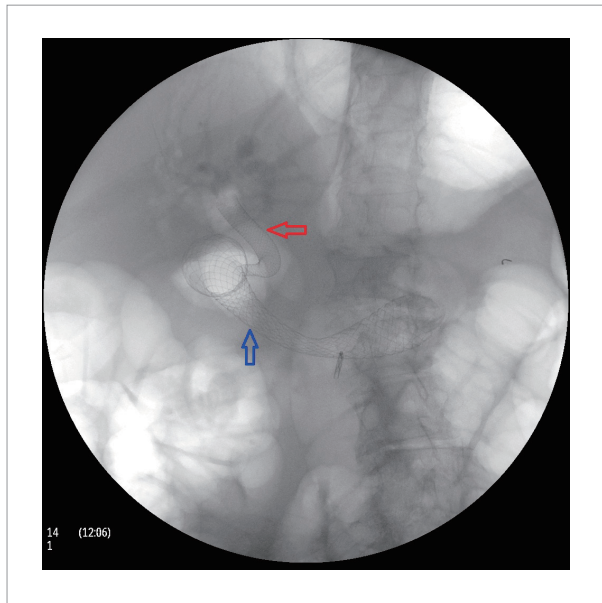


**Figure 4.** Fluoroscopic image showing successful deployment of Wall-stent I fully covered biliary expandable endoprosthesis (8 mm x 60 mm) (arrow). Endoscopic view of the choledochoduodenal stent within the duodenal bulb (inset).

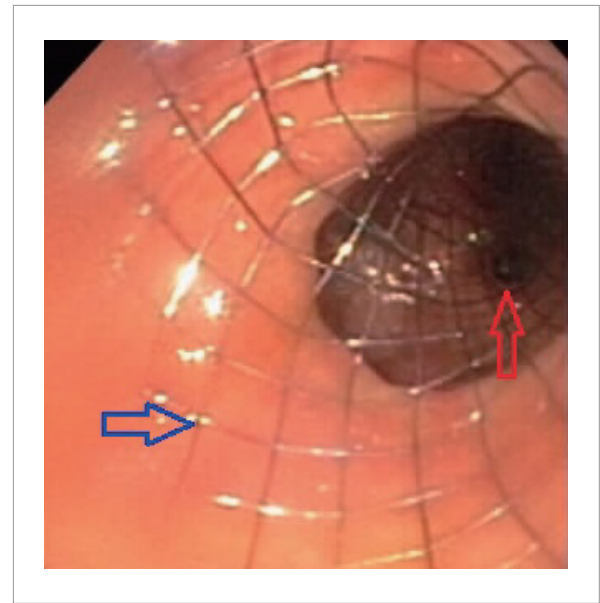
also been published for malignant ampullary lesions causing CBD obstruction.<sup>5</sup> Its major advantages include its immediate availability in the setting of a failed ERCP session, provision for internal and long lasting biliary drainage by the virtue of its anatomic location away from the tumor.<sup>6</sup> This technique has been described to be safer than the percutaneous drainage and more successful than the rendezvous approach.<sup>7,8</sup> Notable complications from the procedure are local peritonitis, cholangitis and stent migration.<sup>8</sup> Combined choledochoduodenostomy and duodenal

stent placement in the setting of advanced pancreatic cancer were previously reported.<sup>9</sup> However, no case has been reported on simultaneous EUS-CDS and duodenal stent placement in a patient with malignant ampullary tumor. The average duration of stent patency varied from three to nine months.<sup>10,11</sup>

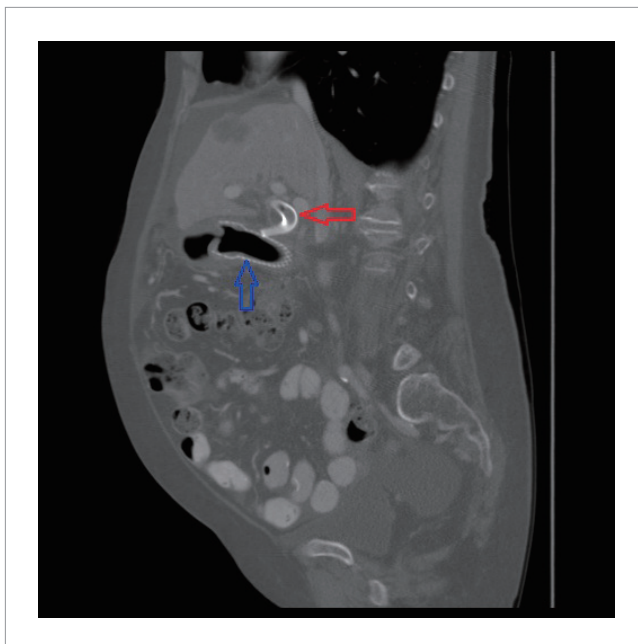
Our patient had advanced recurrent ampullary cancer not amenable to therapy and underwent an EUS-CDS through the duodenal bulb with successful relief of biliary obstruction. This procedure is more valid for end-stage malignancies where patients



**Figure 5.** Fluoroscopic visualization after successful deployment of choledochoduodenostomy (red arrow) and duodenal (blue arrow) stents.



**Figure 6.** Endoscopic visualization after successful deployment of duodenal (blue arrow) and choledochoduodenostomy (red arrow) stents.



**Figure 7.** CT visualization after successful deployment of choledochoduodenostomy (red arrow) and duodenal (blue arrow) stents.

are wary of undergoing more invasive surgical therapies. With a good success rate and lesser morbidity and mortality compared to other techniques, this procedure offers an alternative palliative therapy for patients with combined biliary and duodenal obstructions.

### References

1. Ferrucci JT Jr., Mueller PR, Harbin WP. Percutaneous transhepatic biliary drainage: technique, results, and applications. *Radiology* 1980; 135:1-1
2. Smith AC, Dowsett JF, Russell RC, Hatfield AR, Cotton PB. Randomized trial of endoscopic stenting versus surgical bypass in malignant low bile duct obstruction. *Lancet* 1994; 344:1655-60.
3. Kama NA, Coskun T, Yuksek YN, Yazgan A. Factors affecting post-operative mortality in malignant biliary tract obstruction. *Hepatogastroenterology* 1999; 46:103-7.
4. Kenji Y, Akira S, Kuniyuki T, Hiroshi I, Reiko A, Nobumasa M. EUS-guided choledochoduodenostomy for palliative biliary drainage in case of papillary obstruction: report of 2 cases. *Gastrointestinal Endoscopy* 2006; 64:663-7.
5. Shigetaka Y, Kenji Y, Vikram V, Nobumasa M, Akira S, Masahiro T, et al. Endoscopic ultrasound-guided choledochoduodenostomy for treatment of ampullary cancer. *Clin J Gastroenterol* 2008; 2:55-58.
6. Yamao K, Bhatia V, Mizuno N, Sawaki A, Ishikawa H, Tajika M, et al. EUS-guided choledochoduodenostomy for palliative biliary drainage in patients with malignant biliary obstruction: results of long-term follow-up. *Endoscopy* 2008; 40:340-2.
7. Artifon EL, Ferreira FC, Otoch JP, Rasslan S, Itoi T, Perez-Miranda M. EUS-guided biliary drainage: A review article. *J Pancreas (Online)* 2012; 13:7-17.
8. Hara K, Yamao K, Mizuno N, Hijioka S, Sawaki A, Tajika M, et al. Interventional endoscopic ultrasonography for pancreatic cancer. *World J Clin Oncol* 2011; 2(2): 108-14
9. Harada R, Kawamoto H, Fukatsu H, Tsutsumi K, Fujii M, Kurihara N, et al. Combined endoscopic ultrasound-guided choledochoduodenostomy and duodenal stent placement in a patient with pancreatic cancer. *Endoscopy* 2007; 39:E284-5.
10. Hara K, Yamao K, Niwa Y, Sawaki A, Mizuno N, Hijioka S, et al. Prospective clinical study of EUS-guided choledochoduodenostomy for malignant lower biliary tract obstruction. *Am J Gastroenterol* 2011; 106:1239-45.
11. Komaki T, Kitano M, Sakamoto H, Kudo M. Endoscopic ultrasonography-guided biliary drainage: evaluation of a choledochoduodenostomy technique. *Pancreatology* 2011; 11:47-51.