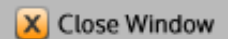




Print



Close Window

Proof



Print

CONTROL ID: 1426805**ABSTRACT FINAL ID:** P1244**TITLE:** Synchronous Association of Cystic Pancreatic Neuroendocrine Tumor and Side-branch Intraductal Papillary Mucinous Neoplasm Diagnosed by Endoscopic Ultrasound**AUTHORS/INSTITUTIONS:** E. Rafiq, M.Z. Bawany, L. De Las Casas, A. Nawras, , University of Toledo Medical Center, Toledo, OH;**ABSTRACT BODY:**

Purpose: Cystic pancreatic neuroendocrine tumor (PNET) is a very rare pancreatic neoplasm while intraductal papillary mucinous neoplasm (IPMN) is an increasingly recognized pancreatic cystic tumor. To best of our knowledge, concomitant association of cystic PNET and side-branch IPMN diagnosed by endoscopic ultrasound (EUS) and fine needle aspiration cytology (FNAC) has not been reported in the literature. We are reporting a patient with this extremely rare association. A 74-year-old woman was referred to our institution due to intermittent epigastric abdominal pain. A CT scan of the abdomen at an outlying facility showed a 1.7-cm cystic lesion in the body of the pancreas as well as a 3.5-cm septal spherical cystic mass with calcification near the tail of the pancreas. EUS was scheduled for further evaluation of the pancreas which showed an anechoic, round and a well-demarcated cystic lesion in the body of the pancreas measuring 16.8 mm x 14.3 mm in size. Communication with the pancreatic duct was identified raising the possibility of IPMN. FNA was performed and cytology was consistent with low grade branch duct IPMN. EUS examination of the pancreatic tail revealed a mixed anechoic and hypoechoic mass with both cystic and solid components measuring 35.1 mm x 25 mm in maximal dimensions. No communication with the pancreatic duct was identified. FNAC showed polygonal cells with granular cytoplasm and rounded monotonous nuclei that on immune staining were positive for synaptophysin, CD 56, and chromogranin A; consistent with a diagnosis of well-differentiated PNET. Subsequently, patient was referred for surgical resection. This case also demonstrates that concomitant pancreatic cystic masses with different EUS morphologic features mandates an individual FNA of each of the cysts for cytology and chemistry to make a definitive diagnosis of potentially coexisting cystic neoplasms.

Methods: N/A

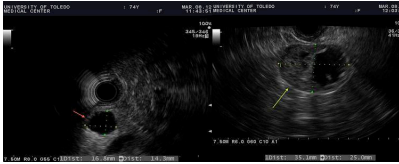Results: N/A

Conclusion: N/A

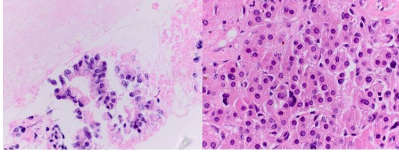
Comparison of the morphologic features and laboratory evaluation of the two pancreatic cystic masses

Cystic Mass	Location	Size	EUS Features	CEA Levels	Amylase Levels
Side-branch IPMN	Body of pancreas	16.8x14.3 mm	Well demarcated anechoic cystic mass	122 ng/ml	6527 U/L
Cystic PNET	Tail of pancreas	35.1x25 mm	Anechoic and hypoechoic with both cystic and solid components	6.3 ng/ml	49 U/L

CEA- Carcinoembryonic antigen



EUS: an anechoic cystic lesion in the body of the pancreas (red arrow) and a mixed anechoic & hypoechoic cystic lesion (yellow arrow) in the tail of the pancreas



IPMN cell block displaying columnar tumor cells and back ground mucin (Left slide). PNET cell block showing tumor cells with rounded monotonous nuclei forming discrete aggregates (Right slide).

ScholarOne Abstracts® (patent #7,257,767 and #7,263,655). © [ScholarOne](#), Inc., 2012. All Rights Reserved.
ScholarOne Abstracts and ScholarOne are registered trademarks of ScholarOne, Inc.



Follow ScholarOne on Twitter

[Terms and Conditions of Use](#)

Product version number 4.0.0 (Build 53)
Build date Jul 18, 2012 15:41:41. Server tss1be0014