



THE UNIVERSITY OF TOLEDO MEDICAL CENTER

# ORTHOPAEDIC MONTHLY

VOLUME 4, ISSUE 2 APRIL 2012

## Orthopaedics to Provide Same-Day Consultations with Other Specialties

Since opening the Orthopaedic Center, the focus has been on providing exceptional patient care. Part of that process has been providing easy access to orthopaedic appointments. Patients are seen within 24 hours of calling the Orthopaedic Center or are seen immediately if there is an emergency.

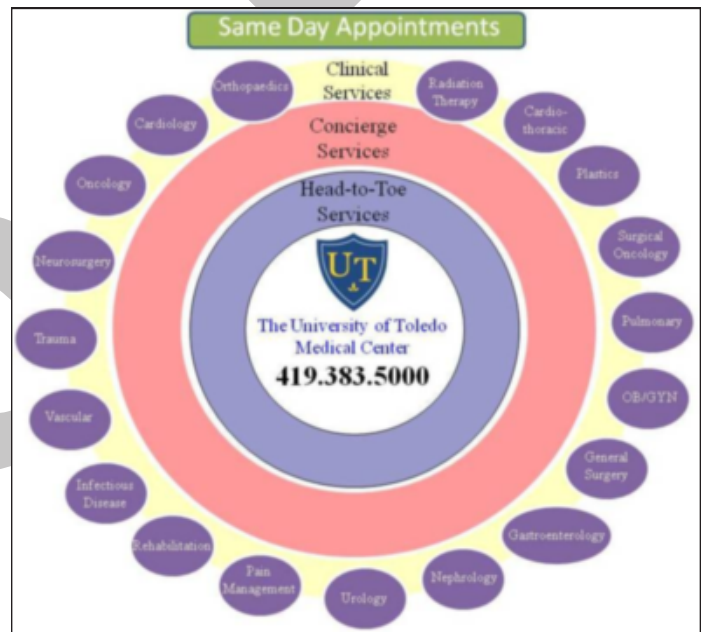
Recently, the Orthopaedic Center has reached an agreement with other services to provide patients with access to same-day consultations with other clinical services. So far, patients will have access to same-day consultations with the following services: cardiology, oncology, neurosurgery, trauma, vascular, rehabilitation, urology, nephrology, gastroenterology, general surgery, OB/GYN, pulmonary, cardiothoracic surgery, and radiation therapy.

This is the first time the Orthopaedic Center will be able to offer this convenience for patients and we are excited about it. These services are looking forward to serving you better and continue to improve our work as a team. They too are motivated to provide the very best care in country and have the enthusiasm and support.

Now that we have assembled the team, not only will the Orthopaedic Center provide these services, but so will the involved services. These services will provide appointments within 24 hours of calling or immediately if there is an emergency.

This process is currently being organized; the Orthopaedic Center will act as a pilot system. Following our experience, the whole system will begin to see patients in this manner. We will have a central phone number for patients to call and get access to these services within 24 hours or immediately for emergencies. Furthermore, we will accept patients from anywhere in the country.

All of these services will be supported by concierge services that will



help patients throughout their appointment. We believe this kind of services goes hand-in-hand with teaching and producing the finest and brightest doctors in America.

We are excited to have other services join us in providing appointments within 24 hours of calling and immediately for emergencies. We are also excited to provide access to same-day consultations for patients who may need care from multiple specialties.

There will be more details to come!

## Supracondylar Spur-Median Nerve Compression

The median nerve can be compressed at many points along its course. About 1 percent of people have a supracondylar spur on the medial side of the humerus about 5 cm from the epicondyle. The nerve runs deep to the supracondylar spur and Struthers ligament,

which may cause entrapment of the nerve. The ligament of Struthers bridges the spur to the medial epicondyle.

*Continued on page 2*

The median nerve usually passes under the ligament along with the brachial artery or its ulnar branch. The median nerve can be pinched underneath the ligament of Struthers.

Clinically, the patient will experience pain, gradual hand weakness, and sensory loss in the median nerve distribution.

Patients may be unable to perform the O.K. sign and may also have a positive Tinel's test. The Tinel's test is considered positive if

symptoms of tingling worsen while tapping on the spur. Occasionally, the spur can be felt.

To treat median nerve compression, physicians will perform a release of the ligament and a decompression of the nerve. They may also perform a resection of the supracondylar process.

## Common Nerve Injuries Around the Shoulder

### Axillary Nerve

The Axillary nerve supplies the deltoid muscle. It arises from the posterior cord of the brachial plexus. The axillary nerve runs anteriorly across the subscapularis muscle. The nerve passes through the quadrangular space. The quadrangular space's boundaries are the teres minor proximally, the teres major distally, the humerus laterally, and the long head of the triceps medially. Within the quadrangular space, the nerve is joined by the posterior humeral circumflex artery. The axillary nerve supplies the muscles of the deltoid and teres minor, giving sensation over the shoulder area. When the nerve is injured, there will be weakness of the shoulder abduction, atrophy of the deltoid, and numbness in the deltoid region. The axillary nerve is commonly injured due to fracture or dislocations of the shoulder joint. When the axillary nerve is injured in the quadrangular space, there will be pain and paresthesia with overhead activity. The injury is usually diagnosed with an angiogram or MRI. It is a difficult diagnosis.

### Musculocutaneous Nerve

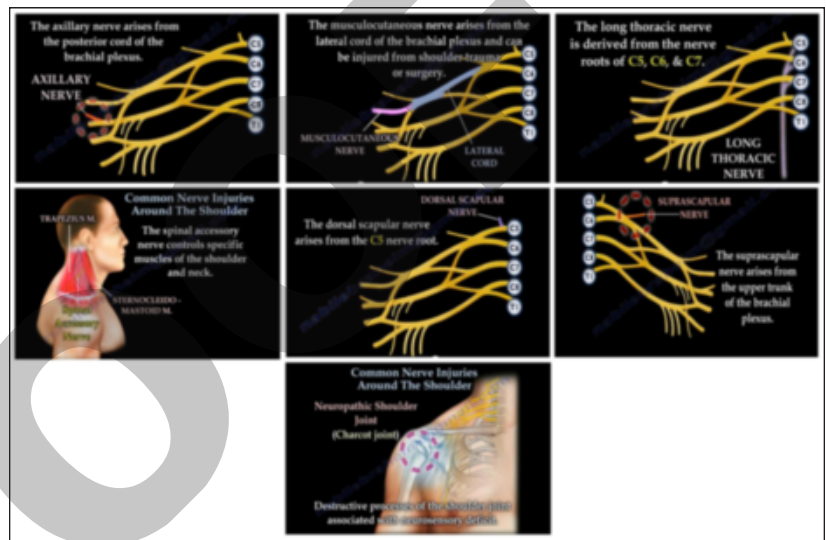
The musculocutaneous nerve supplies the biceps muscle. The musculocutaneous nerve arises from the lateral cord of the brachial plexus and supplies the coracobrachialis and biceps muscles of the shoulder. It also supplies the brachialis muscle on the lateral side of the arm. The musculocutaneous nerve arises from the lateral cord of the brachial plexus and can be injured from shoulder trauma or surgery. Injury to the musculocutaneous nerve may produce weakness of elbow flexion and weakness of forearm supination. To diagnose, physicians will test the biceps muscle by having the patient flex a fully supinated forearm against resistance. With injury to the nerve, the patient will have numbness in the anterolateral forearm (lateral antebrachial cutaneous nerve).

### Long Thoracic Nerve (Serratus Anterior Nerve)

The long thoracic nerve comes from the nerve roots of C5, C6 and C7; it supplies the serratus anterior muscle. Medial winging of the scapula is most commonly caused by deficit in the serratus anterior due to injury to the long thoracic nerve.

### Spinal Accessory Nerve (Trapezius Muscle)

The spinal accessory nerve controls specific muscles of the shoulder and neck. The spinal accessory nerve is the sole motor nerve of the



Common nerve injuries around the shoulder.

trapezius. Lateral winging of the scapula occurs due to injury of the spinal accessory nerve affecting the trapezius. Disruption of this nerve will cause painless limitation of the active elevation of the arm and weakness of the trapezius muscle.

### Dorsal Scapular Nerve (Rhomboids minor, Rhomboids major)

The dorsal scapular nerve arises from the C5 nerve root. It supplies the muscles of the rhomboids minor and major. Injury to the dorsal scapular nerve results in rhomboid winging. The scapula will adopt a similar position to trapezius (lateral) winging with arm elevation.

### Suprascapular Nerve (Supraspinatus muscle, Infraspinatus muscle)

The suprascapular nerve arises from the upper trunk of the brachial plexus. It passes under the transverse scapular ligament at the suprascapular notch. The transverse scapular artery runs above the transverse scapular ligament. The artery and nerve join and then pass through the spinoglenoid notch under the inferior scapular ligament. The suprascapular nerve gives branches to the supraspinatus muscle and branches to the infraspinatus muscle. Nerve compression at the suprascapular notch affects both the supraspinatus and infraspinatus muscles causing decreases in abduction and loss of external rotation. Nerve compression at the spinoglenoid notch affects only the infraspinatus muscle causing loss of external rotation.

Continued on page 3

The spinoglenoid notch compression can occur in volleyball players and is usually associated with cysts, ganglia, or SLAP tears. The infraspinatus muscle is the primary external rotator of the shoulder.

#### Neuropathic Shoulder Joint (Charcot Joint)

Neuropathic shoulder joint refers to a destructive process of the

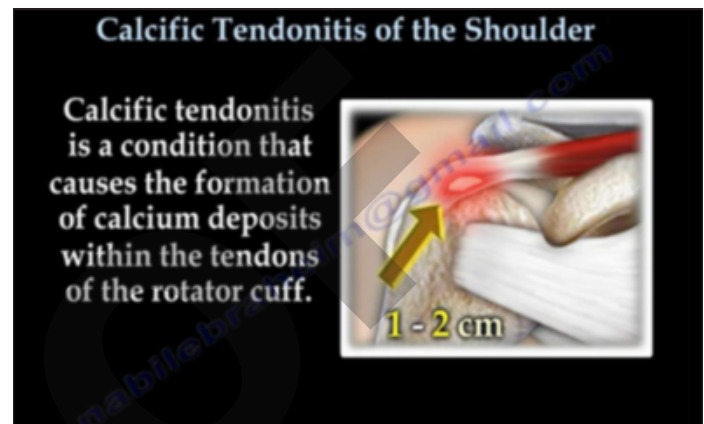
shoulder joint associated with neurosensory deficits. Patients with syringomyelia (cavity within the spinal cord), diabetes mellitus, syphilis, or other neuropathies may be prone to Charcot joint. Physicians should get an MRI of the cervical spine in patients with Charcot shoulder joint.

## Calcific Tendonitis of the Shoulder

Calcific tendonitis of the shoulder is a condition that causes formation of calcium deposits within the tendons of the rotator cuff. These deposits are usually about 1-2 cm in length.

It is a condition that usually occurs with adults around the fourth decade of life and there is a higher occurrence in people who are diabetic. These calcific deposits cause severe pain in the shoulder which is increased by elevation of the arm above the shoulder or by lying on the shoulder. These deposits affect the function of the rotator cuff, causing chemical irritation and shoulder impingement. These deposits may reduce the space between the rotator cuff and the acromion which can lead to subacromial impingement. The calcific deposits are seen on x-rays as lumps or cloudy areas. Ultrasound is more sensitive than x-ray in detecting calcification.

Uthoff's classification system highlights the stages of progression for calcific tendonitis. The first stage is the pre-calcification stage. Here, the tendon site undergoes cellular changes. The second stage is the calcific stage. Here, calcium is excreted from cells and forms calcium deposits in the tendon. There are two phases for this stage. There is the silent phase, which is chalk-like calcification. The second phase is the re-absorptive phase. Here, there are a lot of macrophages, vascular channels, and a toothpaste-like material under pressure that becomes painful. The third stage is the post-calcific stage. During this phase, the calcium deposits start to disappear and a more normal rotator cuff tendon begins to appear.



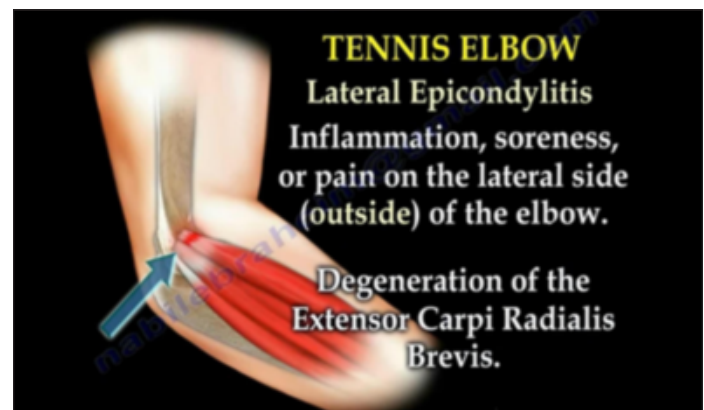
Calcific tendonitis can be treated conservatively with anti-inflammatory medications, physiotherapy, cortisone injections, and needling and lavage. During needling and lavage, deposits are broken-up by puncturing the deposit. Aspirating the calcific material with a lavage, usually under fluoroscopy or ultrasound, may also be used. Surgery is used as a last resort when the calcific tendonitis is painful and is usually done by arthroscopic debridement, with or without acromioplasty.

## Tennis Elbow

Tennis elbow, also known as lateral epicondylitis, is characterized by inflammation, soreness, or pain on the lateral (outside) of the elbow. There is degeneration of the extensor carpi radialis brevis. Tennis elbow is usually seen in patients who perform manual labor or sports which require twisting and extension of the wrist against resistance.

Radial tunnel syndrome is a common differential diagnosis for tennis elbow. Radial tunnel syndrome pain is very similar to the symptoms of tennis elbow. However, pain is usually distal to the lateral epicondyle and radiates down to the forearm. If symptoms of tennis elbow are not resolving with treatment, physicians should rule out the possibility of radial tunnel syndrome.

*Continued on back page*





THE UNIVERSITY OF TOLEDO  
**MEDICAL CENTER**

Department of Orthopaedic Surgery  
The University of Toledo  
3000 Arlington Ave.  
Toledo, Ohio 43614

---

Non-Profit  
Organization  
U.S. POSTAGE  
PAID  
Toledo, OH  
Permit No. 161

---



*Tennis elbow continued*

Physicians may utilize ultrasound evaluation for tennis elbow. Here, the elbow is placed into a semi-flexed position with the hand pronated. Ultrasound is used to visualize and inject the tendon. The transducer is positioned parallel to the lateral epicondyle and the radial head. The radial head is then identified, followed by the bony cortex of the epicondyle; the bony cortex is usually very smooth. The origin of the tendon is then identified; it is usually smooth and homogeneous and has no Doppler flow. The affected tendon may show tears, calcification or thickening.

Treatment for tennis elbow usually involves the following: rest, job modification, non-steroidal anti-inflammatory medications, and physiotherapy (eccentric exercise). If the treatment does not provide adequate relief, patients may be given injections. They may be given blind or under ultrasound-guidance. Blind injections may be used prior to using ultrasound-guidance. Steroids are usually injected, but provide only short-term relief. Platelets with needle fenestration is probably the best treatment, but it is expensive, requires more than one injection, and physicians will have difficulty in getting the method assembled.

When conservative treatment fails, surgical intervention is needed. It is the physicians' last resort. Surgery for tennis elbow involves debridement of the involved tendon. While surgery is usually successful in about 85 percent of patients, it is not successful for all patients. Injury to the lateral collateral ligament should be avoided as it may cause elbow instability.

THE UNIVERSITY OF TOLEDO MEDICAL CENTER  
**ORTHOPAEDIC  
MONTHLY**

---

Editors:

**Dr. Nabil Ebraheim**,  
department chairman  
and professor of orthopaedics,  
and **Dave Kubacki**, assistant  
to the chairman.

---

Neither Dr. Ebraheim nor Dave  
Kubacki have any relationships  
with industry to disclose.

**Department of  
Orthopaedic Surgery**  
3000 Arlington Ave.  
Toledo, Ohio 43614

For appointments, call  
419.383.3761.