



THE UNIVERSITY OF TOLEDO MEDICAL CENTER

ORTHOPAEDIC MONTHLY

VOLUME 4, ISSUE 4 AUGUST 2011

Orthopaedic & Pharmacology Depts. Study Effects of Smoking on Stem Cells

While it is known that smoking is connected to osteoporosis, decreased bone mineral density, increased risk of bone fracture incidence, and increased non-union rates, the effect of smoking on stem cells (specifically mesenchymal stem cells) has been relatively unexplored. With the use of mesenchymal stem cells becoming more common in orthopaedics due to their healing potential, it's become increasingly important to study the effect of smoking on stem cells. A team of researchers from the University of Toledo Medical Center, comprised of doctors (MD's & PhD's) from orthopaedics and pharmacology including Dr. Nabil Ebraheim, Dr. Nader Abraham, Dr. Dong Hyun Kim, Dr. Jiayong Liu, former master's student Greg Lause, and current orthopaedic sciences master's student Samerna Bhat, are in the process of concluding research on this important

topic. According to Dr. Ebraheim, the study of smoking and stem cells is essential.

"For bones to heal, they need stability and vascularity," Dr. Ebraheim said. "The surgeon may fix bones properly, but the fracture may not heal because no one is able to repair it. The repair comes from the mesenchymal stem cells, which come from the blood. If there is no blood in the area, fractures won't heal. There may be good vascularity that gives good mesenchymal stem cells, but if the patient smokes, the mesenchymal stem cell may not be present. The rate of non-union is five times higher in a smoker than a non-smoker. This affects not only bone fractures, but also spine fusions. We hope that with this study that we find not only the toxic harm of smoking, but also how to reverse the effects of smoking."

Continued on page 2

Bipartite Patella

Bipartite patella refers to a failure of the ossification centers of the patella to fuse.

Types of bipartite patella in published data include: inferior pole, lateral margin, and superolateral pole

An example of the bipartite patella is the superolateral pole. Here, the accessory ossification center at the superolateral pole remains un-fused. Physicians will see that the patella consists of two bones; the smaller part is the un-fused segment, is rounded, and is usually located laterally. It can sometimes be confused with a fracture.

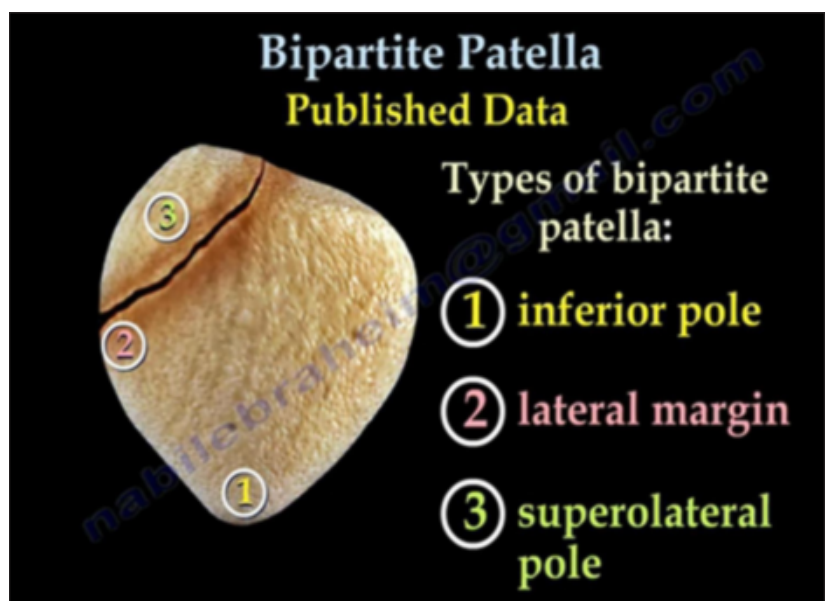
A bipartite patella is usually asymptomatic and is found incidentally, causing symptoms that mimic those of a fracture. Minor trauma or injury can cause the fibrous tissue to become inflamed or irritated.

Treatment for a bipartite patella includes: rest, knee immobilizer, physiotherapy, and non-steroidal anti-inflammatory medications.

If the fragment is small and very painful, it can be excised.

If the fragment is large and painful and conservative treatment fails,

physicians can release the lateral retinaculum to reduce the traction force of the smaller fragment.



The use of mesenchymal stem cells is the hallmark of recent advances in orthopaedics this century. These cells have tremendous potential in healing injured areas of the body and generating new cartilage or bone. When we say mesenchymal stem cells, we are referring to autologous adult mesenchymal stem cells; we are not referring to embryonic stem cells. Adult mesenchymal stem cells are taken from the patient and returned to the same patient.

There has been some research done on the negative effects of cigarette smoke on mesenchymal stem cells in the past. However, researchers at The University of Toledo Medical Center are looking closely at the effects of nicotine (since it is found in other forms of smokeless tobacco) on mesenchymal stem cells. According to Dr. Abraham, their research has proven that smoking has a negative effect on stem cells.

“We all know that tobacco smoking is toxic and contributed to premature death, although cessation of smoking pre-operatively improves bone fractures and bone healing” Dr. Abraham said. “The Orthopaedic Center, in collaboration with Physiology and

Pharmacology, demonstrated that nicotine at accumulated dose levels in heavy smoker inhibits bone formation in all cultures in a dose dependent manner and simultaneously increasing adiposity (i.e. joint formation). These novel findings describe a novel finding consistent within the concept that nicotine or tobacco smoke inhibits bone formation and increases joint formation.”

Dr. Kim echoed Dr. Abraham’s words.

“There are limited studies that have analyzed the quality or number of mesenchymal stem cells present in different tissues,” Dr. Kim said. “We have found that nicotine decreases osteogenesis and cell proliferation of mesenchymal stem cells, that nicotine decreases heme-oxygenase-1 expression which is a very important gene for anti-reactive oxygen species, and that when treated with the inducer of HO-1 on osteogenesis, the effect of nicotine was reversed.”

Clearly, it is an exciting time for the University with the work being done by the Departments of Orthopaedics and Physiology and Pharmacology.

Patellar Tendon Rupture

A patellar tendon rupture refers to a rupture of the tendon that connects the patella to the tibia.

A rupture often occurs at the lower pole insertion site of the patella and can be associated with degenerative changes. Rupture most often occurs in patients younger than 40 years of age. When the tendon is ruptured, the quadriceps muscle pulls the patella upward.

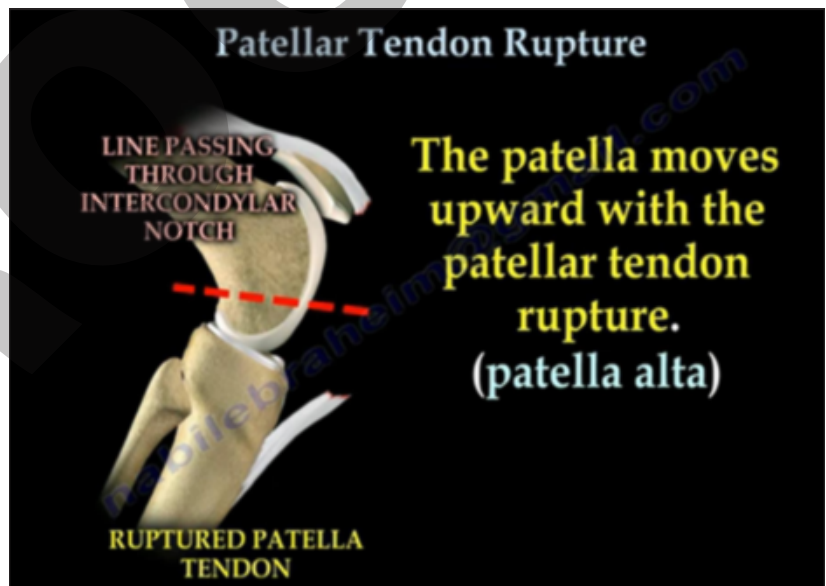
To identify if the patella is high, low, or normal, physicians will measure the Blumensaat’s line as a guide. Here, the knee will be flexed to at least 30 degrees, and then a line will be drawn through the roof of the intercondylar notch and usually touches the tip of the patella.

The patella moves upward with the patellar tendon rupture; this is called patella alta.

Associated risk factors for patellar tendon rupture include the following:

- Rheumatoid arthritis
- Diabetes
- Chronic renal failure
- Systemic corticosteroid therapy
- Chronic patellar tendonitis
- Degenerative changes of the patellar tendon

AP and lateral x-rays are usually taken during the radiologic evaluation. Patella alta can be seen on the lateral view, which means a superior migration of the patella, usually above Blumensaat's line.



MRI is probably the most effective means to assess the patellar tendon, especially if other intraarticular or soft tissue injuries are suspected.

To treat patellar tendon ruptures, physicians need to surgically reattach the tendon to the bone. The knee should be kept in extension and in an immobilizer for approximately 4-6 weeks.

Patellar Fractures

To understand patella fractures, it's helpful to first look at the anatomy of the knee. The knee is composed of the femur (thigh bone), the tibia (shinbone), the fibula (calf bone), and the patella (kneecap). The patella is attached to the quadriceps tendon at the top and the patellar tendon at the bottom. Movement of the patella across the knee is normally a gliding, smooth movement.

A patellar fracture is an injury to the kneecap. These fractures are commonly caused by a direct blow to the kneecap or from a fall. Types of patellar fractures include the following: transverse fractures, upper or lower pole fractures, comminuted fractures, vertical fractures, and osteochondral fractures.

Transverse fractures can be displaced or non-displaced. In a displaced fracture, the patella can be pulled apart by the attached thigh muscles. Here, patients will be unable to do active extension of the knee.

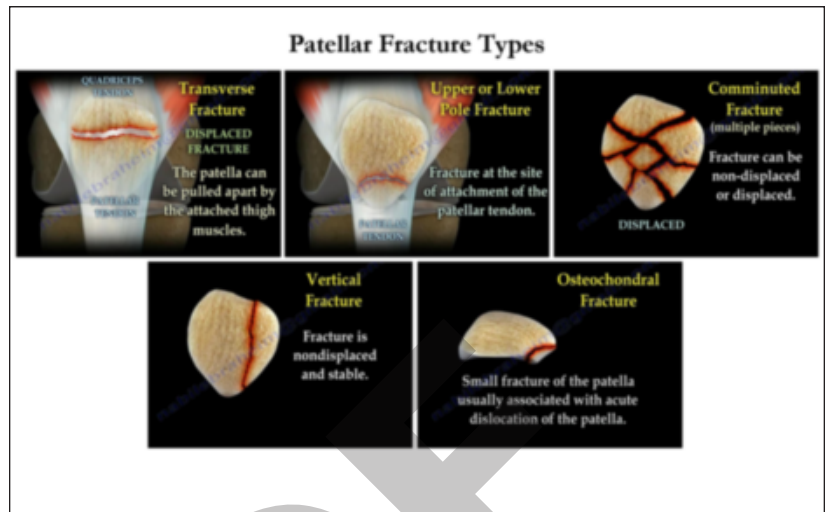
An upper or lower pole fracture refers to fractures at the site of the attachment of the patellar tendon.

Comminuted fractures refer to fractures in multiple pieces; these types of fractures can be displaced or non-displaced. These fracture types shatter into three or more pieces and are very unstable and difficult to treat.

Vertical fractures are non-displaced and stable. In these types of fractures, the fragments usually stay in place during healing.

Osteochondral fractures are small fractures of the patella that are usually associated with acute dislocation of the patella. Osteochondral fractures are usually located in the facet area of the patella.

Let's look at an example of treatment for a transverse patella fracture. If the fracture is non-displaced or minimally displaced, the patient is able to actively extend the knee with full extension. The patient is



usually treated with a knee immobilizer or a brace. If the patient has a transverse displaced fracture, they are unable to extend the knee. This displaced transverse patellar fracture is usually treated by surgery. Reduction of the fracture is achieved with a reduction clamp. K-wires are then placed perpendicular to the fracture. A figure-8 tension band wire is applied for compression of the fracture. These tension band wires convert anterior distractive forces to compressive forces at the articular surface. As the knee moves in flexion, there will be compression at the articular surface. The other technique involves the use of cannulated lag screws with a tension band. Here, a wire is passed through the screws and across the patella in a figure-8 tension band.

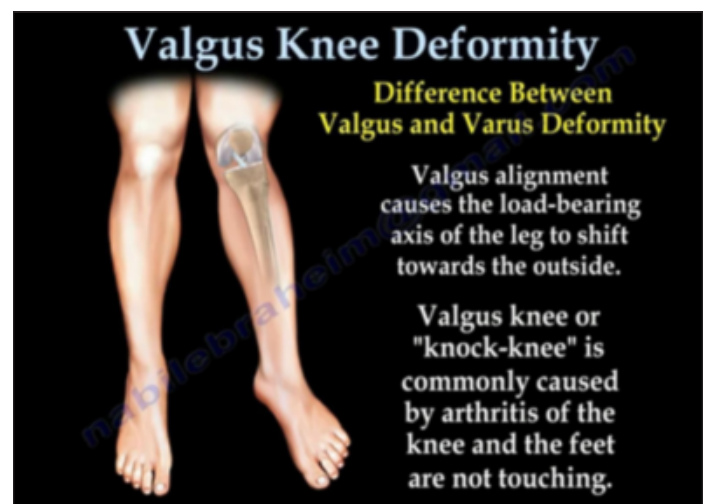
A partial patellectomy usually involves excision of the distal pole and smaller fragments. The patellar tendon is reattached anteriorly with sutures. A total patellectomy is usually indicated for comminuted fractures and displaced fractures that cannot be reconstructed. Here, the bony fragments are excised before reattachment of the patellar tendon.

Valgus Knee Deformity

When the knee is not perfectly aligned from side-to-side, either a valgus or varus malalignment may occur.

In a valgus deformity, the load-bearing axis of the leg shifts towards the outside. A valgus knee or a "knock-knee" is commonly caused by arthritis of the knee. The patient cannot make their feet touch each other. Varus alignment, conversely, causes inward angulation and stress on the medial (inner) part of the knee. Here, the feet will touch each other, but the knees will be apart. Varus knee deformity is typically known as "bow-leg," referring to an outward bowing of the leg in relation to the thigh.

Severe valgus deformities place stress on the articular cartilage, bone, and ligaments of the knee joint which causes the progression of knee osteoarthritis.



Continued on back page



THE UNIVERSITY OF TOLEDO
MEDICAL CENTER

Department of Orthopaedic Surgery
The University of Toledo
3000 Arlington Ave.
Toledo, Ohio 43614

Non-Profit
Organization
U.S. POSTAGE
PAID
Toledo, OH
Permit No. 161



Valgus Knee Deformity continued

Valgus knee deformities have intrinsic complications. If you correct the valgus knee deformity, the patella could potentially sublux laterally. Correction of the deformity can often tether or stretch the peroneal nerve.

If there is unicompartmental arthritis, the valgus deformity can be treated by distal femoral osteotomy and correcting the axis to neutral. If there is tricompartmental arthritis with moderate valgus, the deformity can be treated by a total knee replacement. In these cases, the knee replacement may require lateral release for patellar subluxation. Physicians need to be aware and careful of injury to the peroneal nerve.

If peroneal nerve palsy develops post-operatively, physicians should remove all constrictive dressings and flex the knee. If the arthritis is tricompartmental with severe valgus, physicians should perform an osteotomy of the femur and total knee replacement; this is a very difficult problem.

THE UNIVERSITY OF TOLEDO MEDICAL CENTER
**ORTHOPAEDIC
MONTHLY**

Editors:

Dr. Nabil Ebraheim,
department chairman
and professor of orthopaedics,
and **Dave Kubacki**, assistant
to the chairman.

Neither Dr. Ebraheim nor Dave
Kubacki have any relationships
with industry to disclose.

**Department of
Orthopaedic Surgery**
3000 Arlington Ave.
Toledo, Ohio 43614

For appointments, call
419.383.3761.