

THE UNIVERSITY OF TOLEDO
MEDICAL CENTER

APPROVED FOR THE AMA PRA CATEGORY 1 CREDIT, SEE INSERT FOR DETAILS

THE UNIVERSITY OF TOLEDO MEDICAL CENTER

ORTHOPAEDIC MONTHLY

VOLUME 4, ISSUE 1 JANUARY 2010

Patients with Complicated Orthopaedic Injuries Have Great Outcomes and Positive Attitudes



Pamela Sauder

Iwish I could go into the waiting room and tell the other patients to hang in there and that things do get better," Pamela Sauder said. "It's not easy, but they should know they are in good hands."

Sauder is an Orthopaedic Center success story. In April 2008, Sauder was riding her motorcycle on a windy day and was blown into a guardrail, causing significant injuries. Life Flight took her to the Orthopaedic Center, where she underwent several complicated procedures to treat her right lower extremities, with injuries to her hip, knee and ankle. According to Sauder, it was her team's positive attitude that helped her get through the difficult times.

"The doctors kept telling me over and over, 'What do you do when a road is closed? You find a detour,'" Sauder said. "He was so reassuring and kept telling me that 'We'll make something work for you.' My confidence in the care I received never wavered."

While these are extraordinary accounts, they happen every day in the Orthopaedic Center. Another patient, Daniel Przyojski, defied all odds when he returned to bodybuilding following a traumatic injury to his leg while working for a steel company.



Daniel Przyojski

There were 10,000 pounds of steel on a cable when it unraveled and landed on his leg, nearly severing it. Several years later, Przyojski returned to the bodybuilding arena and won the masters division at the 2001 Mr. Michigan Bodybuilding Championships in Dearborn, Mich. According to Przyojski, he was able to reach that height again due to unparalleled care and personal determination.

"When the accident came along, I set my mind that one day I would walk back up to the stage and compete again. It didn't matter if I won," Przyojski said. "With the exceptional care I received and hard work, I was able to achieve my goals."



Jean Elsea

And then there is Jean Elsea, a 90-year-old patient who had sustained a distal femur fracture following a motor vehicle accident in 2001. Elsea was originally treated at an outside institution, but developed degenerative joint disease, causing deformity and pain in her left knee. She underwent total knee arthroplasty in November 2009 to correct the deformity, eliminate her arthritis, and reduce her pain. By mid-December, she was busy planning a trip to San Francisco for six weeks.

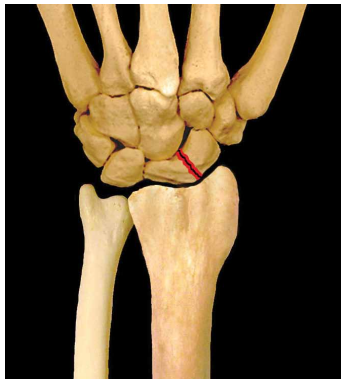"It's great to be feeling better and being able to do the things I want to do," Elsea said. "I'm looking forward to vacationing in San Francisco and visiting some vineyards while I'm out in California."

Despite these bad injuries, a positive, reasonable outcome is usually achieved. Through optimism, patience, and determination, these patients have recovered very well. They share their stories to show other patients that there is hope when you have complicated orthopaedic injuries. ■



Important Blood Supply

For bones to heal properly following injuries, it's important for the blood supply to remain healthy and intact. With some parts of the body, fractures can significantly hinder the blood supply, leading to several complications. The two major complications from loss of blood supply are non-union and avascular necrosis. Non-union refers to a bone that fails to heal, and avascular necrosis refers to a deterioration or death of bone due to insufficient blood supply. Common areas of the body with blood supply issues following fractures include the scaphoid, femur, talus, and fifth metatarsal.

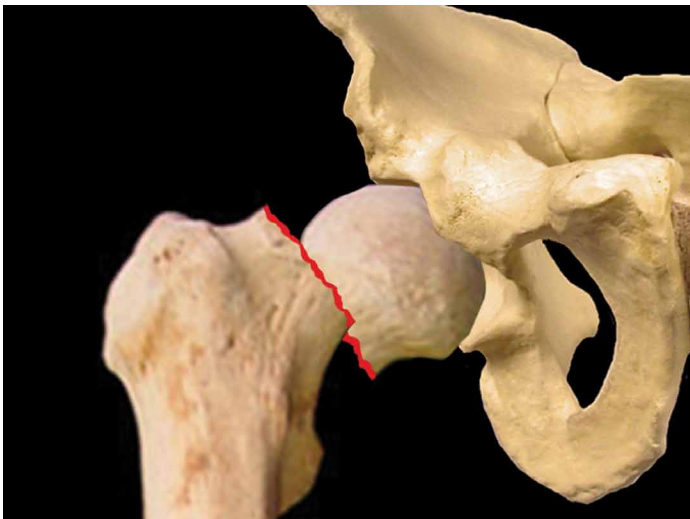


The scaphoid

The scaphoid, which is the most common wrist bone to fracture, is the small bone of the wrist located on the thumb side where the wrist bends. Because the blood supply enters retrograde (blood enters further from the heart) to the proximal scaphoid, there are greater chances for complications the more proximal the injury. Scaphoid fractures can be difficult to diagnose and may be occult, so they are best evaluated with MRI imaging.

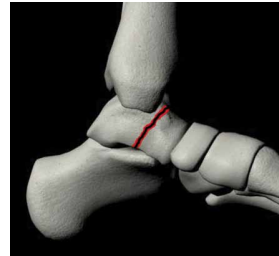
These fractures have a high risk of delayed union, non-union, and avascular necrosis with proximal pole fractures. Treatment for non-displaced and stable fractures can be achieved with cast immobilization while surgery is required for displaced fractures.

The femur, usually referred to as the thigh, is the bone of the upper leg. Femoral neck fractures have a high risk of avascular necrosis and non-union, and they have a high mortality rate (roughly 25 percent). Because femoral neck fractures are often the result of high-energy trauma, they usually have high-angle, shear-type breaks, which make them vulnerable to blood supply disruption. Specifically, displaced femoral neck fractures disrupt ascending retinacular arteries resulting in avascular necrosis. MRI imaging is



Femoral neck fracture

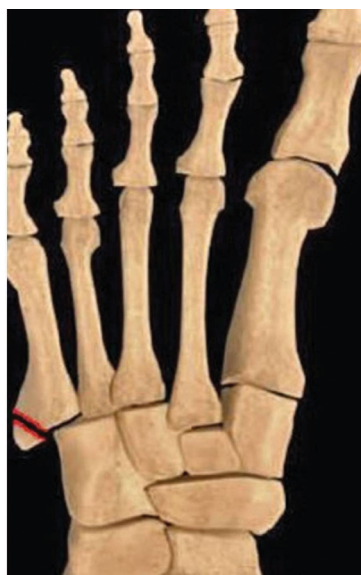essential in detecting occult fractures and for diagnosing avascular necrosis. Treatment for patients over 65 is usually achieved through total hip arthroplasty or hemiarthroplasty. For patients under the age of 65, the most common treatment is open reduction and internal fixation.



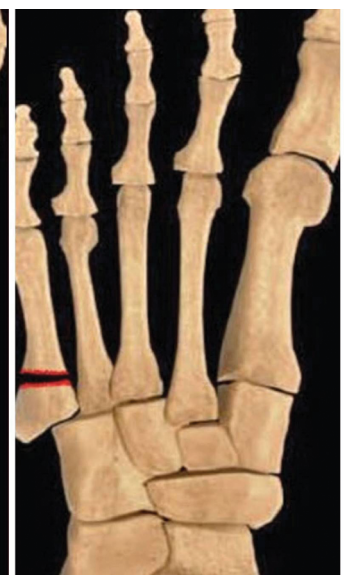Talus

Another bone in the body commonly associated with blood supply issues is the talus. The talus connects the leg to the foot and is responsible for upward and downward movement of the ankle. With the calcaneus, it is essential in inward and outward movement of the foot. Because the surface of the talus is composed mostly of cartilage (60 percent), there are few places for blood to reach the bone. Therefore, this is another bone with a retrograde blood supply. Talus fractures are best evaluated by CT scan. Surgery is required for displaced talar neck fractures, while reduction and stabilization are the preferred treatments for fractures of the talar body. Approximately 20 percent of all talus fractures result in avascular necrosis.

The fifth metatarsal, which is the long bone on the outside of the foot that connects to the little toe, is another bone with blood supply issues following fractures. Avulsion fractures are zone I injuries usually occurring along the insertion of the lateral band of the plantar aponeurosis. Treatment is achieved by closed means, usually with a short-leg cast or a stiff-soled shoe. Jones' fractures are zone II injuries and usually result from tensile stress along the lateral border of the proximal fifth metatarsal. Treatment involves either a short-leg cast or surgery. Proximal diaphyseal stress fractures are zone III injuries and are relatively rare. They are usually the result of repetitive cyclic loading and have a high tendency for non-union. Treatment for proximal diaphyseal stress fractures involves fixation with bone grafting. ■



Avulsion Fracture

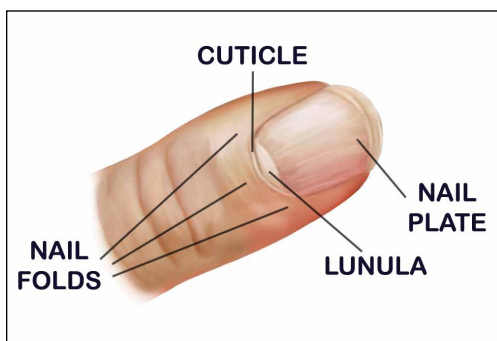


*Proximal Diaphyseal Stress Fracture
High Incidence of Non-Union*

What are Toenails and Fingernails?

We all have fingernails and toenails. Some of us bite them, and some of us file them, but not everyone knows exactly what finger and toenails are.

Fingernails and toenails are composed of a tough, hardened protein called keratin. Keratin is made and cultivated in the nail's matrix, which is a hidden part of the nail found under the cuticle. The cuticle is the tissue that overlaps the sides and the base of the finger or toenail. The remaining components of finger and toenails are the nail plates, nail beds, nail folds, and lunulas. Nail plates are the visible part of the nail. The nail bed is the skin found directly below the nail plate. The nail fold refers to the skin that frames and provides support for the nail on the sides and base. Finally, the lunula is the whitish half-moon looking object at the base of the nail.



Healthy finger and toe nails are usually smooth and uniform in color and consistency. They grow at a rate of an eighth of an inch per month. It takes approximately three to six months to completely re-grow a fingernail, while it takes 12 to 18 months to re-grow a toenail.

As we know, nails can break, dry out, or become infected. Infections are often caused or worsened by several factors, including:

- Aggressive exercise
- Improperly fitting shoes
- Exposure to unclean environments
- Dirty socks

Changes in nail bed or nail plate color can sometimes be signs of deeper health issues. Patients should see a doctor if they notice any of the following: yellow discoloration; separation of your nail from the nail bed; opaque or white nails; curled nails; or nail pitting.

To maintain healthy nails, patients would be wise to try the following:

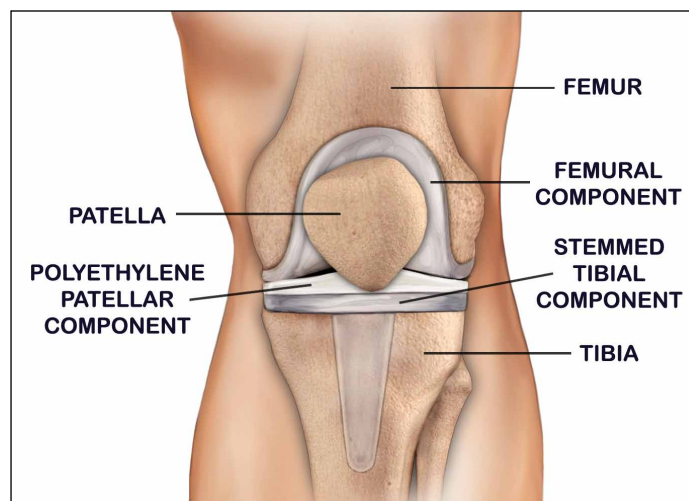
- Abstain from biting your nails or picking at your cuticles
- Keep your nails clean
- Trim your nails regularly
- Wear properly fitting shoes ■

Patient-Specific Knee Replacements

With an aging population, joint replacements are becoming more common in orthopaedic surgery. Included in the joint replacement category are knee replacements. Roughly 581,000 knee replacements are performed each year in the United States. When conservative measures don't give patients adequate pain relief or don't restore function, total knee replacements provide a viable and safe option.

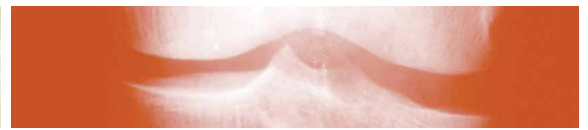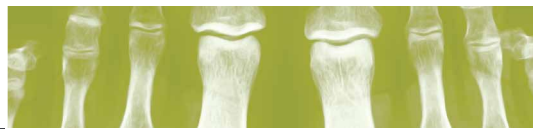The knee, which is the largest joint in the body, connects three lower extremity bones: the femur (thigh bone), the tibia (shin bone), and the patella (kneecap). Articular cartilage outlining the surface of the three bones allows unimpeded motion and provides cushion where the bones make contact with each other. The synovial membrane is the remaining anatomical component and is responsible for releasing a lubricating fluid to reduce friction caused from bones rubbing together.

Candidates for total knee replacement usually suffer from three forms of arthritis: osteoarthritis; rheumatoid arthritis; and post-traumatic arthritis. Osteoarthritis, which usually occurs in people over the age of 50, is characterized by a softening and wearing away of the cartilage providing cushion between bones. The ultimate result is bone-on-bone friction, which causes pain, stiffness, and decreased range of motion. Rheumatoid arthritis is



a disease characterized by inflammation of the synovial membrane. This inflammation damages cartilage and causes pain, stiffness, and decreased range of motion. The third type of arthritis, post-traumatic arthritis, is the long-term result of an injury such as a ligament tear or fracture.

continued on page 4



Knee Replacements *continued from page 3*

Patients with arthritis will likely experience the following symptoms:

- Pain
- Inflammation
- Deformity
- Stiffness

If patients do not respond to conservative treatment in the form of medications, physical therapy, or injections, they are likely candidates for total knee replacement surgery.

The goal of total replacement surgery is to remove diseased bone and cartilage and replace it with an artificial joint made of metal and plastic. The patient's knee will be placed in a bent position to

expose all joint surfaces. Once the incision is made, surgeons remove the damaged cartilage and bone. While there are several different total knee replacements, three components are typically involved: the femoral component, the tibial component, and the patellar component. After removing the damaged cartilage and bone, surgeons insert the artificial joint. During this phase, physicians will bend and rotate the knee to ensure proper joint alignment. The procedure takes approximately two hours.

Companies such as Zimmer, Biomet and others are working hard to increase the quality of knee replacements. With designs such as Zimmer's patient-specific instruments, patients receive a truly customized surgery experience. Through the use of MRI imaging of a patient's true knee anatomy and surgical planning using advanced software, custom-fitted position guides and cutting blocks are created that are specifically designed for the patient's knee replacement surgery. Therefore, surgeons have the ability to not only customize the patient's surgery experience, but also provide an implant that is uniquely matched to the patient's lifestyle. It's almost like going to a tailor and being custom-fit for a suit.

For over 90 percent of patients, there will be a substantial decrease in pain and an improvement in range of motion. In roughly three to six weeks, patients may be able to resume most of their daily activities. However, physicians may suggest avoiding some activities that may accelerate normal wear and cause the replacement to loosen. ■

THE UNIVERSITY OF TOLEDO MEDICAL CENTER
ORTHOPAEDIC MONTHLY

Editors: Dr. Nabil Ebraheim, department chairman and professor of orthopaedics, and Dave Kubacki, assistant to the chairman.

Neither Dr. Ebraheim nor Dave Kubacki have any relationships with industry to disclose.

For medical questions you would like to see addressed in this newsletter, please e-mail Dave at david.kubacki@utoledo.edu.

Department of Orthopaedic Surgery
 3000 Arlington Ave
 Toledo, Ohio 43614
 For appointments, call 419.383.3761.

UTMC 5/05/2010

Non-Profit
 Organization
 U.S. POSTAGE
 PAID
 Toledo, OH
 Permit No. 951

Department of Orthopaedic Surgery
 The University of Toledo
 3000 Arlington Ave
 Toledo, Ohio 43614

