

THE UNIVERSITY OF TOLEDO
MEDICAL CENTER

APPROVED FOR THE AMA PRA CATEGORY 1 CREDIT, SEE INSERT FOR DETAILS

THE UNIVERSITY OF TOLEDO MEDICAL CENTER

ORTHOPAEDIC MONTHLY

VOLUME 2, ISSUE 3 MARCH 2008

Orthopaedic Center Increases its Capabilities

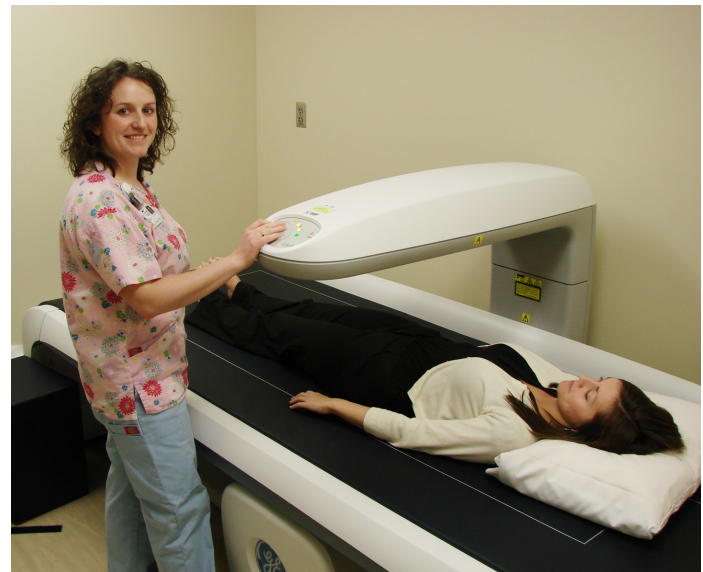
Additional Services Provide Patients Better Access, Service and Convenience to Orthopaedic Care

The health-care field is ever-changing. Every day, researchers across the country are searching for new techniques and better treatment options for patients. In addition to these important innovations, we try to find new ways to better serve patients.

The University of Toledo Orthopaedic Center was established to eliminate traditional barriers to orthopaedic care, providing access to timely appointments with world-class physicians. With our pledge to see patients within 24 hours of calling the Center, we've eliminated that barrier. However, we want to refine this process and make it even easier for the patient.

On Feb. 3, the Center expanded services to include Saturday morning appointments for patients who cannot make a weekday appointment. We felt it was essential to give patients even better access to doctors. During this clinic, we accept all orthopaedic patients with injuries and conditions from neck to toe and every bone and joint in between. This improved access complements our current pledge to see patients within 24 hours of calling the Center. If there is an emergency, of course, we see the patient immediately.


The UT Orthopaedic Center has also increased its service capabilities. The DEXA scan, a high-tech piece of equipment used to determine bone mineral density, is now being utilized. This additional capability will be essential for osteoporosis testing. Another service that will be available soon is an in-house MRI. More than physical machines, we have also increased our sports medicine efforts partnering with Dr. David Weldy, UT assistant professor of family medicine, who specializes in fitness. Internal medicine services are being added to the Orthopaedic Center through a partnership with Dr. Samih Bittar, UT assistant professor of medicine. These doctors supplement the Center's orthopaedic, pain management and rehabilitation doctors. Our



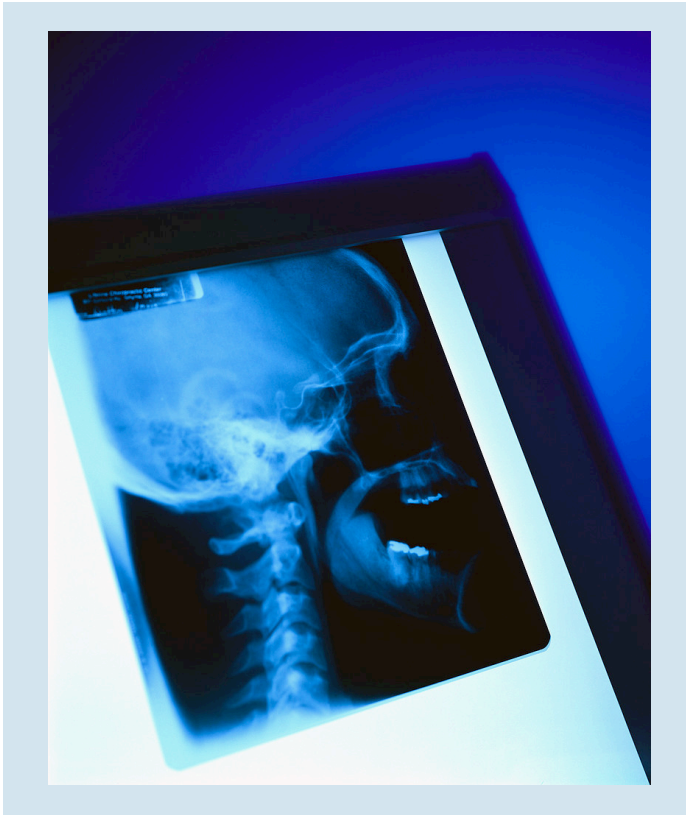The DEXA scan is now being utilized to help with osteoporosis testing

surgeons treat conditions from neck to toe and every bone and joint in between including fractures, trauma, spine, shoulder, knee, hip, foot and ankle, hand and oncology.

As always, our goal has been to make all of these services convenient for patients. Although we have increased the capabilities of the Orthopaedic Center, all of these services are still available in one convenient location. In addition, we continue to offer free valet parking and a coffee bar. For patient convenience, the Center provides expansive waiting areas and a large flat panel television for patient comfort. As soon as you walk in the door, you will be greeted by a Team Ortho member who will guide you through the process. We want your experience to be stress-free and pleasant. We are constantly trying to find ways to better serve our patients and we will continue to refine and expand our services to reflect their needs.



Neck Pain: Causes and Treatment



Every structure in the body has a unique purpose and design. They were created out of necessity, not by chance. The cervical spine, better known as the neck, has several important functions that we may sometimes forget. Because the neck moves more and is less protected than the rest of the spine, roughly two-thirds of the population report neck pain at some point in their life.

The neck is composed of seven bones, called vertebrae that begin in the upper torso and end at the base of the skull. With the help of muscles and ligaments, the neck provides stability to the spine and allows motion. The neck has two other very important responsibilities: supporting the head, which can weigh 15 pounds, and allowing the spinal cord to pass through, connecting the brain to nerves of the body.

There are three basic movements for the neck's range of motion. First, the neck's ability to move side-to-side is called rotation. Second, the ability to move forward and backward is called flexion and extension. Third, the neck's ability to move head to shoulder is called lateral bending.

As stated earlier, the neck is susceptible to injury because of its range of motion and lack of protection compared to other parts of the body. Common causes of neck pain include muscle strain, inflammatory disease, cervical disk degeneration, disk herniation and injury.

Good posture is essential in safeguarding yourself from neck pain. When you have good posture, your neck, spine and head are in alignment. Activities that require you to lean over however, such as sitting at a desk, can cause the neck to become fatigued. When

the neck becomes fatigued, it eventually becomes strained. Inflammatory disease, such as rheumatoid arthritis, also leads to neck pain. When the neck is overused, joints become swollen and stiff, reducing the neck's range of motion. Arthritis harms the joints in the neck and leads to severe pain as a result of stiffness.

Cervical disk degeneration is also responsible for causing neck pain. Here, the gelatin-like center of the disk degenerates and the space between the vertebrae narrows. The disks, which should act as shock absorbers between the bones, are unable to cope with the additional applied stress causing further degeneration. This narrowing of the spinal canal is known as spinal stenosis. The additional stress may also cause the disks to protrude and put pressure on the spinal cord. This condition is known as a herniated cervical disk.

Injuries may also cause neck pain. Most often, neck pain arising from an injury is the result of a motor vehicle accident, fall or contact sport. Often these injuries cause pain because the neck is extended beyond its normal limits. Here, pain is either the result of hyperextension (backward motion beyond normal limits) or hyperflexion (forward motion beyond normal limits). With hyperextension or hyperflexion, the soft tissue around the neck is stretched past its normal limits.

Patients should seek medical attention if pain is persistent and continuous; radiates down the arms and legs; occurs following an automobile accident or other injury; or is accompanied by numbness, headaches, weakness or tingling.

To identify the cause of neck pain, orthopaedic surgeons may utilize several different tests such as family history and physical examination; MRI evaluation of the spinal cord and nerve roots; CT scan to evaluate the bone and spinal cord; X-ray; or an EMG, where needles are placed in the arm and muscles with wires attached to measure the electrical activity of nerves, to evaluate nerve and muscle function.

While most neck pain can be treated with rest, medication, immobilization, exercise, activity modification, physical therapy or a combination of these, surgical intervention is sometimes needed.

March 2008 Word Search

H E R N I A T I O N E O Z F A
 U J U N I N N Y N Y F S F P G
 W X A P I Y S O O E I T Z I E
 C A D L G V I D I T A Y S Y M
 N H D W W T T E I S S L E E G
 Z F L Q A B L N H U N R V Z M
 T W X T C C O I R M U E T G P
 D C O G I D E E Z T R X T J L
 B R F V N U M N C T G P P X I
 U S A E Z U U A E G N W N C E
 D L T V H S R B F N A S B K W
 C P B L D F R D N O I X E L F
 F L A G G A R T N P Q N E X Z
 C X N E E S I T I S R U B F Y
 H Q V S C A P U L A E W P K G

CLAVICLE
 SCAPULA
 HUMERUS
 TENDONITIS
 BURSTITIS
 FRACTURE
 VERTEBRAE
 ROTATION
 FLEXION
 EXTENSION
 HERNIATION
 EMG
 MRI

Why My Shoulder Hurts?

If you think about it, there are few daily tasks that don't involve the use of your shoulders. Because the shoulder is the most movable joint in the body, it is somewhat unstable. Overuse and shoulder instability can lead to several different varieties of shoulder pain.

The shoulder is composed of three bones: the clavicle (collarbone), the scapula (shoulder blade), and the humerus (upper arm bone). Motion is controlled by two joints: the acromioclavicular joint (AC joint) and the glenohumeral joint. The AC joint is located between the acromion and the clavicle while the glenohumeral joint is the ball-and-socket joint that allows the arm to rotate in a circular motion. Supported by muscles, tendons and ligaments, the rotator cuff holds the ball at the top of the humerus in the socket and provides strength and mobility to the shoulder joint. Injuries often arise from the shoulder's soft tissue being over- or underused. In addition, the shoulder's anatomy can also play a role in shoulder pain. Common shoulder pain causes include tendonitis, bursitis, injury/instability, arthritis, rotator cuff tears and fractures.

Tendonitis often causes pain which is the result of the tendon being overused. A tendon connects the muscle to bone or other tissue. Tendonitis is usually the result of degenerative changes that take place over several years. This can be characterized either as an acute (following an overuse problem) injury or a chronic (degenerative disease due to age) injury.

Bursitis is another overuse disease that affects the shoulder. Excessive use often leads to inflammation of the bursa—the fluid filled sac around the joints—which may limit the use of the shoulder. The bursa is responsible for lessening the friction caused by shoulder movement.

Shoulder instability is a common problem that results in shoulder pain. Because the ball of the upper arm is larger than the socket that holds it, it is often subject to injury. This anatomical anomaly causes instability if muscles, and tendons or ligaments are disrupted.

Another common shoulder problem is a dislocated shoulder. The shoulder joint is the most commonly dislocated joint in the body and is usually has a high recurrence rate in young patients. Shoulder dislocation is usually caused by a strong force that pulls the shoulder outward, popping the ball of the humerus out of the shoulder socket. Often, this motion overwhelms the muscles because they are unprepared to resist the excessive force. Putting the shoulder back into position is accomplished through a process called reduction. This procedure is usually done while the patient is sedated or relaxed. Dislocations may be associated with nerve injuries such as the axillary nerve and brachial plexus. If a young patient is unable to lift his or her arms following reduction of a shoulder dislocation, there is usually an axillary nerve injury. However, if an elderly patient is unable to lift his or her arms following reduction of a shoulder dislocation, there is usually a rotator cuff tear. An MRI may be necessary to determine the injury.

Another shoulder injury patients often experience is a separated shoulder. A separated shoulder results when a force separates the

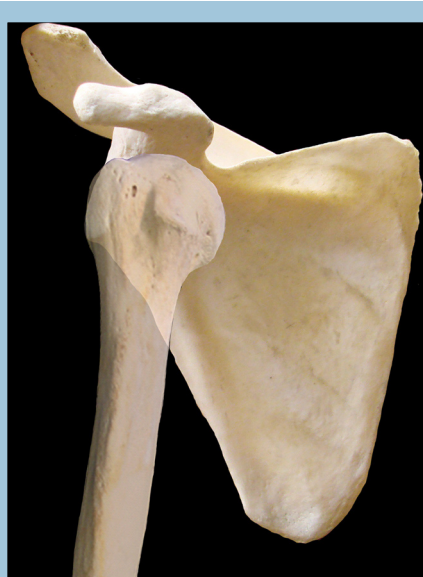collarbone from the shoulder blade. The shoulder blade moves downward from the weight of the arm and creates a bump or bulge above the shoulder.

Arthritis and rotator cuff tears can also occur. Arthritis involves wear-and-tear changes with inflammation of the joint causing swelling, stiffness and pain. Rotator cuff tears refer to a tear in one of the four tendons that blend together to attach to the humerus. These tendons transfer forces from the shoulder blade to the arm, providing motion and stability.

Fractures are also a shoulder injury concern. A shoulder fracture refers to a partial or total crack through one of the three bones of the shoulder. Fractures are usually the result of an impact injury. Clavicle (collarbone) fractures are usually treated conservatively, although there is a high incidence of non-union in distal third fractures. Patients with scapula (shoulder blade) fractures should be admitted and observed. Here, there is a concern of pulmonary complications. Fractures of the humerus are usually treated conservatively. Stiffness is often a concern for elderly patients. Therefore, early rehabilitation is usually necessary.

Certain signs indicate that patients should seek medical attention, including an inability to carry objects or use an arm; deformity of the shoulder joint; pain that occurs at night or while resting; pain that persists beyond a few days; an inability to raise the arm; or severe bruising or swelling around the joint.

Doctors often use a variety of methods to determine shoulder pain, including x-rays, MRIs, injections and arthrograms. While shoulder pain can be treated conservatively, surgical intervention is sometimes required to alleviate shoulder pain.

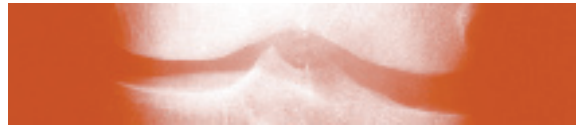
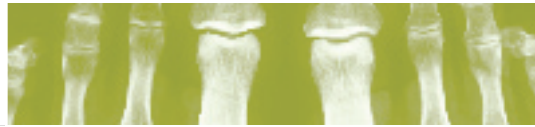

Rendering of an anterior shoulder dislocation

Orthopaedic Center Chosen to Provide Care for Veterans

Members of the Veterans Affairs (VA) on Glendale Avenue have a new home for orthopaedic care: The University of Toledo Orthopaedic Center. Since January of 2008, the organizations have been working on a partnership to help patients of the VA in need of orthopaedic care. According to Dr. Thomas Gross of the VA on Glendale, this partnership was needed in order to respond to the overwhelming number of elderly patients who need hip, knee and shoulder treatment. Because of the high demand, veterans were being placed on a waiting list for one to two years before they were able to receive treatment. To help alleviate this local and national problem, the VA's have engaged in contracts to help the veterans out. According to Dr. Gross, UT's Orthopaedic Center was a perfect fit.

"There is no doubt, UTMC is the best," Gross said. "The Orthopaedic Clinic is well established, it's in close proximity to us, the staff is excellent and we believe the Orthopaedic Center will serve our population very well."



“The Center is absolutely amazing, It is a long way from what it used to be when I worked here! We used to be in two small hallways and look at where it is now. It’s exciting for all the doctors and the community to see this kind of growth.” - Colleen Skie

Dr. Marty Skie’s wife Colleen passes out cookies at the Orthopaedic Center on Valentines Day

THE UNIVERSITY OF TOLEDO MEDICAL CENTER

ORTHOPAEDIC MONTHLY

Editors: Dr. Nabil Ebraheim, department chairman and professor of orthopaedics, and Dave Kubacki, assistant to the chairman.

Neither Dr. Ebraheim nor Dave Kubacki have any relationships with industry to disclose.

For medical questions you would like to see addressed in this newsletter, please e-mail Dave at david.kubacki@utoledo.edu.

Department of Orthopaedic Surgery
3000 Arlington Ave
Toledo, Ohio 43614
For appointments, call 419.383.3761.

MUO 608 208 25C



Department of Orthopaedic Surgery
The University of Toledo
3000 Arlington Ave
Toledo, Ohio 43614

