

## Ferrier and the Study of Auditory Cortex

Henry E. Heffner, PhD

● David Ferrier was a British physician who studied the localization of function in the cerebral hemispheres during the latter half of the 19th century. Using stimulation and ablation techniques, Ferrier demonstrated that auditory cortex was located in the superior temporal gyrus of the monkey and that ablation of auditory cortex resulted in deafness. Although he was substantially correct, Ferrier's location of auditory cortex was not accepted by his contemporaries, and his observations of cortical deafness were, until recently, discounted by modern researchers. Just why his findings were rejected is of interest to the study of cortical function.

(Arch Neurol 1987;44:218-221)

During the first half of the 19th century, it was commonly believed that there was no differentiation of function in the cerebral hemispheres but that each function could be conducted by any area. After 1860, however, various researchers began presenting evidence showing that sensory and motor functions were localized in specific areas of the cerebral cortex. One of the principal localizers was a British physician, David Ferrier (Fig 1),<sup>1</sup> who studied the organization of the cortex using stimulation and ablation techniques. Because the conclusions of Ferrier's

research were not always in agreement with those of his contemporaries, he became involved in controversy concerning the exact location of certain functions.<sup>2</sup>

A major controversy surrounding Ferrier's work concerned his study of auditory cortex in primates, specifically, his placement of auditory cortex in the superior temporal gyrus and the claim that ablation of this gyrus resulted in deafness. Ferrier's location of auditory cortex was rejected by his contemporaries, and his observations of deafness following superior temporal gyrus lesions have been discounted by modern researchers. Yet it was long ago established that Ferrier was correct in his location of auditory cortex, and it now appears that he was substantially correct in his observations of cortical deafness. Why, then, were his conclusions not accepted?

### FERRIER'S WORK ON AUDITORY CORTEX

David Ferrier began his work on brain localization using the technique of electrical stimulation, which had been developed by Fritsch and Hitzig.<sup>3</sup> This technique allowed him to infer the function of a particular cortical area by stimulating it and noting the animal's movements. Ferrier's<sup>4</sup> initial work consisted of a series of stimulation studies on the brains of birds and mammals, and he improved on Fritsch and Hitzig's<sup>3</sup> technique by using faradic or alternating current instead of galvanic or direct-current stimulation.

Using the stimulation technique to map the cortex of monkeys, Ferrier's<sup>5</sup> placed auditory cortex in the upper

two thirds of the "superior temporo-sphenoidal convolution", ie, the superior temporal gyrus (Fig 2). Ferrier found that stimulating this area resulted in the following: "pricking of the opposite ear, head and eyes turn to the opposite side, pupils dilate widely." Yet how did Ferrier know that he was stimulating an auditory area and not a somatic or motor area? Ferrier said, "These phenomena resemble the sudden start and look of astonishment or surprise which are caused when a loud sound is made in the ear opposite the hemisphere which is being irritated." In other words, electrical stimulation of the superior temporal gyrus produced the same startle reaction as sounding a "shrill whistle" close to an animal's ear.



Fig 1.—David Ferrier (from Critchley<sup>1</sup>).

Accepted for publication Aug 4, 1986.  
From the Laboratory of Comparative Hearing, Bureau of Child Research, University of Kansas, Parsons.

Reprint requests to Laboratory of Comparative Hearing, Bureau of Child Research, University of Kansas, PO Box 738, Parsons, KS 67357 (Dr Heffner).

Ferrier's placement of auditory cortex was remarkably correct given the relatively crude techniques available at that time. Recent studies have confirmed that auditory cortex is indeed located in the posterior two thirds of the superior temporal gyrus, although it is mostly buried in the depths of the sylvian fissure.<sup>6</sup> However, Ferrier was aware of the fact that auditory cortex included the entire gyrus and not just the superficial portion.

Locating auditory cortex by means of electrical stimulation was only the first step. To complete the identification, it was necessary to remove auditory cortex by surgical means and observe the effect on hearing. It was here that Ferrier's difficulties began.

During Ferrier's time, it was commonly believed that the cortex was the seat of all sensation.<sup>7</sup> This view arose from observations of clinical symptoms in human patients, especially those suffering blindness as the result of cortical injury. It was supported, in turn, by the results of visual cortex lesions in animals and generalized to other modalities as illustrated by Ferrier's statement, "For what is true of the... sight centre is true, *mutatis mutandis*, of the other sensory centres." Thus, Ferrier and his contemporaries expected ablation of auditory cortex to result in complete and permanent deafness.

Ferrier<sup>8</sup> conducted two series of ablation studies with monkeys, the first of which was published in 1876. This series consisted of 25 monkeys with various cortical lesions, of which three monkeys had bilateral and two had unilateral lesions of the superior temporal gyrus. Ferrier tested his animals by carefully observing their response to sounds. He determined if they were "roused" by sounds, whether they turned their head and looked when called, or whether they would respond in any way when called by name. He gave these tests to monkeys with auditory lesions and those with nonauditory lesions. Although he lacked the conditioning techniques currently used to test animals, his tests were carefully conducted and he seemed well acquainted with each animal's preoperative responses to sound.

Ferrier made two discoveries about auditory cortex lesions. First, he found that bilateral ablation of the superior temporal gyrus, unlike ablation of other areas, had the immediate effect of rendering the animals unresponsive to sound. This was the result he was looking for, and it provided conclusive evidence that he had found

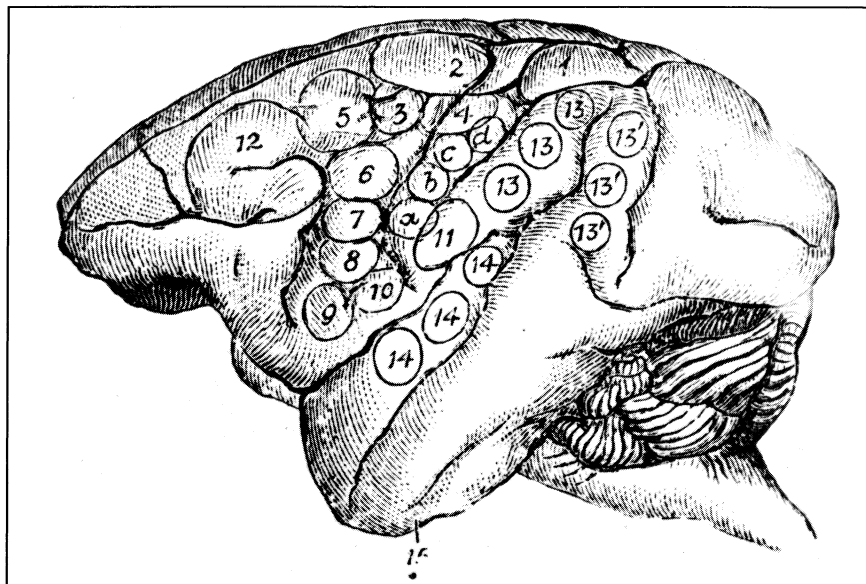


Fig 2.—Ferrier's figure illustrating location of auditory cortex (No. 14) as determined by electrical stimulation (from Ferrier,<sup>3</sup> p 410).

auditory cortex. Second, Ferrier found that unilateral lesions of auditory cortex resulted in deafness in the contralateral ear—a phenomenon he demonstrated by plugging the ipsilateral ear with cotton and observing the animal's reactions to sound. Given the evidence of the ablation studies along with that of the stimulation studies, Ferrier concluded that auditory cortex was located in the posterior two thirds of the superior temporal gyrus.

One limitation of his study, however, was the fact that the animals were tested for only a few hours or days after surgery. This was because the surgeries were performed without aseptic precautions, and the animals either soon developed infections or were killed before infection could confound the results. As a result, Ferrier was unable to determine whether the animals would have recovered their hearing over time.

A few years later, Ferrier, in collaboration with Gerald Yeo,<sup>9</sup> embarked on a second series of ablations, this time using aseptic procedures. Of the 33 cases in this series, only two were used to further examine the location of auditory cortex. The first animal, which came to be known as "monkey F," received bilateral lesions of the superior temporal gyri and was reported to be totally deaf 13 months after the surgery. The second animal received a bilateral lesion of the mid-temporal gyrus, which had no noticeable effect on its hearing. With this study, Ferrier had replicated his earlier finding of cortical deafness and

had demonstrated that auditory cortex was not located in the midtemporal gyrus.

Monkey F proved to be Ferrier's main case and was shown to a number of other researchers. He reported the following:

The animal was exhibited, six weeks after the operation, before a specially invited number of the physiologists attending the International Medical Congress in London in August 1881. While it was climbing about before the audience a percussion cap was suddenly exploded in its neighbourhood without causing the slightest start or sign of perception—in marked contrast to the behaviour of its hemiplegic companion exhibited at the same time.<sup>9</sup>

As a result, Ferrier believed that he had conclusively shown that auditory cortex was located in the superior temporal gyrus.

#### THE CONTROVERSY

Ferrier's conclusions concerning the location of auditory cortex initially met little opposition. Other researchers had performed lesions of the temporal lobe in dogs and had also found auditory deficits.<sup>10</sup> Although the deficits in dogs appeared to be somewhat transitory, Ferrier<sup>11</sup> had previously noted the existence of species differences and had stated that dogs would not show the same degree of impairment as would monkeys and humans.

A few years later, however, physiologist Edward Schäfer began to perform ablation studies on monkeys. His first study, published with Victor

Horsley,<sup>12</sup> included six cases with unilateral and one with bilateral ablation of the superior temporal gyrus. Although one of the unilateral cases appeared to have a hearing loss in the contralateral ear, the tests on the other five were inconclusive. However, the bilateral case, unlike Ferrier's, appeared to have no hearing loss at all. At this point, Schäfer was unwilling to commit himself and stated that his results were not sufficient to either corroborate or refute Ferrier's earlier observations.

In a second study, performed in conjunction with Sanger Brown,<sup>13</sup> Schäfer made a more detailed study of the effects of cortical lesions on hearing. This time he observed the effect of bilateral lesions in the superior temporal gyrus in six monkeys. Failing to find deafness in any of his cases, he proceeded to question Ferrier's results. His first step was to disregard Ferrier's first series of lesions because of the short survival times, which left Ferrier with only one case, that of monkey F. Schäfer then suggested that monkey F was probably deaf before Ferrier had operated on it. He thereby concluded that auditory cortex could not be located in the temporal lobe of the monkey.<sup>14</sup>

Schäfer's attack aroused an immediate response in Ferrier. Ferrier<sup>15</sup> replied that Schäfer's lesions were incomplete and went on to expound on the importance of distinguishing between "reflexive" hearing and "hearing proper." Ferrier then reviewed all evidence that indicated that auditory cortex was located in the superior temporal gyrus. This consisted of his own studies of stimulation and ablation as well as two cases in the clinical literature, which indicated that bilateral temporal lesions in humans resulted in deafness.

In reviewing the ablation evidence, Ferrier published some actual notes of his observations of monkey F. Interestingly, these observations indicated that the animal occasionally showed signs of hearing. Ferrier attributed these signs to either mere coincidence, to a simple startle reaction, or to the possibility of an incomplete lesion. However, these signs were sufficient for Schäfer<sup>16</sup> to conclude that the monkey could hear and that Ferrier had no case.

The consensus of 19th-century scientists on this issue was expressed by William James.<sup>7</sup> After describing the work of Ferrier and Schäfer, James noted the following:

Terrible recriminations have, as usual,

ensued between the investigators, Ferrier denying that Brown and Schaefer's ablations were complete, Schaefer that Ferrier's monkey was really deaf. In this unsatisfactory condition the subject must be left, although there seems no reason to doubt that Brown and Schaefer's observation is the more important of the two.

In short, James concluded that superior temporal gyrus lesions in monkeys probably did not result in deafness and, therefore, that the location of auditory cortex in the monkey had not yet been determined.

#### MODERN CONFIRMATION OF FERRIER'S RESULTS

Little new information was obtained about auditory cortex in the period immediately following Ferrier and Schäfer. However, beginning in the 1930s, new techniques in neuroanatomy, electrophysiology, and behavior were developed, which led to a rapid advance in knowledge of the nervous system. With regard to Ferrier's first point concerning the location of auditory cortex, the neuroanatomical and electrophysiologic studies indicated that he was correct; auditory cortex in the monkey is located in the posterior two thirds of the superior temporal gyrus. That most of it lies buried in the sylvian fissure would probably have come as no surprise to Ferrier<sup>15</sup> as he had argued with Schäfer that the entire gyrus had to be removed to produce deafness.

If Ferrier was correct in locating auditory cortex, then was he also correct in his observation of a hearing loss following ablation of the superior temporal gyrus? Until recently, the answer to this question would have been no.

During the 1930s and 1940s, the effect of auditory cortex lesions on the detection of sound was studied using cats and dogs. Although some studies found that bilateral lesions resulted in substantial hearing losses, others found little or no effect. However, the failure to find a deficit following a lesion has always been considered more significant than reports of deficits resulting from similar lesions.<sup>7,11</sup> As a result, it came to be accepted that auditory cortex ablation had no significant effect on the detection of sound.<sup>17</sup> No further large-scale investigations were conducted on this point, and by 1950 the issue was considered closed.

There remained the possibility that cortical lesions might produce a hearing loss in humans, and occasional reports of cortical deafness following

bilateral stroke continued to appear.<sup>18</sup> However, these reports were not universally accepted because it could not be definitely proved that the stroke was the cause of the hearing loss, and the results of the animal studies were often cited as demonstrating that cortical injury did not produce a hearing loss.<sup>19</sup>

Recent evidence, however, has reopened the issue of cortical deafness in monkeys. In a study originally designed to determine the effect of superior temporal gyrus lesions on auditory discrimination, it was found that bilateral ablation resulted in a profound hearing loss in Japanese macaques.<sup>20</sup> Specifically, the animals were rendered totally deaf for a period of a few days to 13 weeks, depending on the extent of the lesions. Following this period, the animals' hearing began to slowly recover, particularly for low-frequency sounds, although they never completely regained normal levels. Indeed, large hearing losses were noted as long as one year after surgery.

To further explore this deficit, a second study<sup>21</sup> was conducted to determine if unilateral lesions produced a hearing loss in the ear contralateral to the lesions, as Ferrier<sup>8</sup> had noted in his first study. Testing each ear individually with earphones both before and after surgery, it was found that unilateral lesions of the superior temporal gyrus did indeed result in a transient hearing loss in the contralateral ear. This loss was milder than that observed following bilateral ablation, and hearing thresholds recovered to normal or near-normal levels after a few weeks.

Given these results, it now appears that Ferrier was substantially correct in his description of the effect of superior temporal gyrus lesions. Ferrier's monkey F was probably profoundly, if not totally, deaf when it was demonstrated at the International Medical Congress six weeks after surgery. The fact that it occasionally showed some signs of responding to loud sounds indicates that it was probably not completely deaf. Furthermore, Ferrier's observations of a contralateral hearing loss following unilateral ablation were also accurate. The fact that Ferrier tested his unilateral cases immediately after surgery made it easier to detect this deficit, as monkeys recover rapidly from this type of hearing loss.

The problem lies, then, not so much in Ferrier's observations but in the fact that everyone at that time was expecting auditory lesions to result in

complete and permanent deafness. Although Ferrier's<sup>15</sup> last article on the subject suggests that he might have settled for less than absolute deafness, his contemporaries would not have accepted it. Schäfer, in particular, was convinced that auditory cortex lesions would result in total deafness, and his animals, which tended to have smaller lesions, all displayed obvious signs of hearing. Thus, the prevailing view that the cortex was the seat of sensation prevented researchers from realizing that auditory cortex lesions could result in anything other than complete and permanent deafness.

As were our 19th-century predecessors, we also have been limited by our preconceptions. Once it had been decided that those studies that found no effect of cortical lesions on sound detection outweighed those claiming to find an effect, the possibility of a cortical hearing loss was never seriously reconsidered. Those researchers who noticed that monkeys were initially unable to discriminate between different sounds following cortical ablation tended to attribute it to other factors such as "postoperative amnesia."<sup>22</sup> Indeed, until recently, no modern study looked at the effect of cortical lesions on auditory thresholds in

primates.

In his studies, Ferrier was mistaken neither in his location of auditory cortex nor in his description of the effects of ablating auditory cortex. Instead, the interpretation of his results was limited by the prevailing views on the role of the cortex. Such preconceptions are inevitable in any scientific inquiry.

This work was supported by research grant NS 12992 from the National Institutes of Health, Bethesda, Md.

I am grateful to Rickye Heffner, PhD, and Bill Porter for commenting on an earlier draft of this manuscript and to Banny Rucker, MLS, and Jane O'Bryan for their help in locating the historical sources.

## References

1. Critchley M: *The Citadel of the Senses*. New York, Raven Press, 1986, p 101.
2. Glickstein M: Ferrier's mistake. *Trends NeuroSci* 1985;8:341-344.
3. Fritsch G, Hitzig E: Über die elektrische Erregbarkeit des Grosshirns. *Arch Anat Physiol Wissen Med* 1870;37:300-332.
4. Ferrier D: Experiments on the brain of monkeys. *Proc R Soc Lond Biol* 1875;23:409-432.
5. Ferrier D: *The Functions of the Brain*. London, Smith Elder & Co, 1876.
6. Merzenich MM, Brugge JF: Representation of the cochlear partition on the superior temporal plane of the macaque monkey. *J Neurophysiol* 1973;24:193-202.
7. James W: *Principles of Psychology*. New York, Henry Holt & Co, 1890.
8. Ferrier D: The Croonian lecture: Experiments on the brain of monkeys: Second series. *Philos Trans R Soc Lond Biol* 1876;165:433-488.
9. Ferrier D, Yeo G: A record of experiments

on the effects of lesion of different regions of the cerebral hemispheres. *Philos Trans R Soc Lond Biol* 1885;175:479-564.

10. Luciani L: On the sensorial localisations in the cortex cerebri. *Brain* 1814;7:145-160.
11. Ferrier D: *The Localisation of Cerebral Disease*. London, Smith Elder & Co, 1878.
12. Horsley V, Schäfer EA: A record of experiments upon the functions of the cerebral cortex. *Philos Trans R Soc Lond Biol* 1889;179:1-45.
13. Brown S, Schäfer EA: An investigation into the functions of the occipital and temporal lobes of the monkey's brain. *Philos Trans R Soc Lond Biol* 1889;179:303-327.
14. Schäfer EA: Experiments on special sense localisations in the cortex cerebri of the monkey. *Brain* 1888;10:362-380.
15. Ferrier D: Schäfer on the temporal and occipital lobes. *Brain* 1889;11:7-30.
16. Schäfer EA: On the functions of the temporal and occipital lobes: A reply to Dr Ferrier. *Brain* 1889;11:145-166.
17. Neff WD, Diamond IT, Casseday JH:

Behavioral studies of auditory discrimination: Central nervous system, in Keidel WD, Neff WD (eds): *Handbook of Sensory Physiology*. New York, Springer-Verlag NY Inc, 1975, vol 2, pp 307-400.

18. Jerger J, Weikers NJ, Sharbrough FW III, et al: Bilateral lesions of the temporal lobe: A case study. *Acta Otolaryngol Suppl* 1969;258:1-52.
19. Rosati G, Bastiani PD, Paulino E, et al: Clinical and audiological findings in a case of auditory agnosia. *J Neurol* 1982;227:21-27.
20. Heffner HE, Heffner RS: Hearing loss in Japanese macaques following bilateral auditory cortex lesions. *J Neurophysiol* 1986;55:256-271.
21. Heffner HE, Heffner RS, Porter WE: Effect of auditory cortex lesions on absolute thresholds in macaques. *Neurosci Abstr* 1985; 11:547.
22. Evarts EV: Effect of auditory cortex ablation on frequency discrimination in monkey. *J Neurophysiol* 1952;15:443-448.