



THE UNIVERSITY OF TOLEDO MEDICAL CENTER

ORTHOPAEDIC MONTHLY

VOLUME 5, ISSUE 3 APRIL 2014

Orthopaedic Center Expanding Service and Convenience for Quality Care

The Department of Orthopaedic Surgery at the University of Toledo is excited to announce exciting advances to the care we are providing at the UT Orthopaedic Center! Beginning March 2014, the Orthopaedic Center will schedule all UTMC Health Science Campus employees for an immediate appointment with an available Orthopaedic Medical Provider. The Center will schedule employees for an appointment at a date/time of their choosing be it on their lunch break, or another time convenient to them. A liaison will help facilitate these important employee visits.

In addition to urgent employee visits, another modification to the center will be our hours of operation. The Monday through Friday hours of operation will be extended to 7am-7pm, as well as

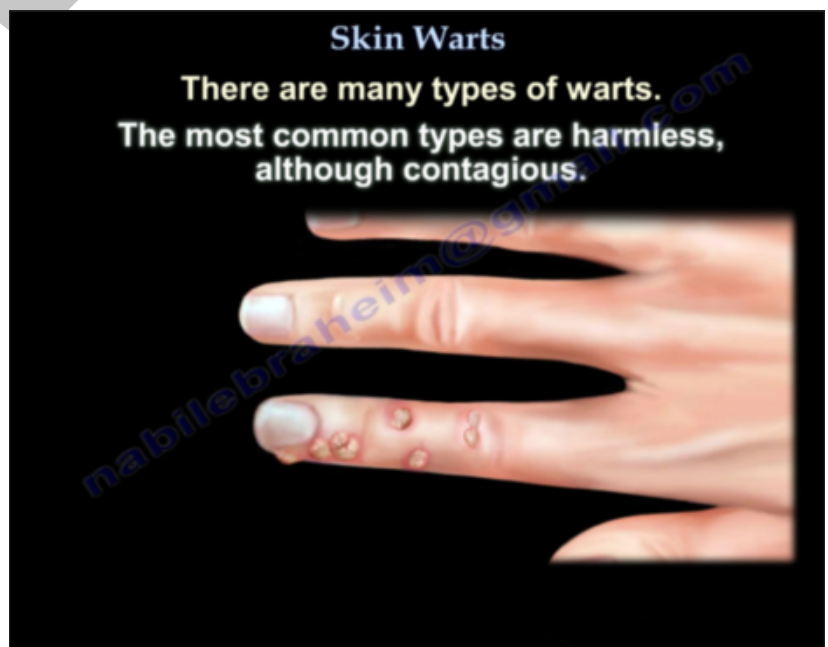additional Saturday hours of 8am-4:30pm becoming available in the near future.

The UT Orthopaedic Center has assembled 11 physicians to provide comprehensive services from neck to toe, including fractures and conditions of the spine, shoulder, elbow, hand, hip, knee, foot & ankle, and sports medicine. Patients have convenient access to all services in one location as the Orthopaedic Center houses laboratory, digital imaging, bracing, and physical therapy services. The Orthopaedic Center strives for excellence in patient satisfaction by providing quality access, service and convenience to its patients and employees of the University of Toledo Health Science Campus.

Skin Warts

Skin warts are a solid blister, a small round growth that looks like a cauliflower, and they are caused by a virus infection (HPV - human papillomavirus). There are many types of warts. The most common types are harmless, although contagious. A person with a broken area of skin may be subject to contracting the virus. There can be multiple skin warts. They usually disappear after several months, but they may last for years and could also recur. Some say that you get warts from touching frogs and toads. Skin warts, however, come from human viruses, not from frogs and toads.

The most common warts appear on the hands. Verruca vulgaris is a raised wart with a roughened surface. The can also occur on the face, genitals, or soles of the feet. Warts are thickened skin tissue. There are many ways to treat warts and many topical products can be used. A topical treatment containing salicylic acid is better than using a placebo. Cryotherapy can also be useful for treating warts. All treatments are meant to remove the wart, but it may regrow after it is removed. Using silver nitrate is also an option, but it may pigment the skin. Overall, warts are difficult to treat, and there is no cure for the wart virus. Patients should not come into contact with other people's warts. They also



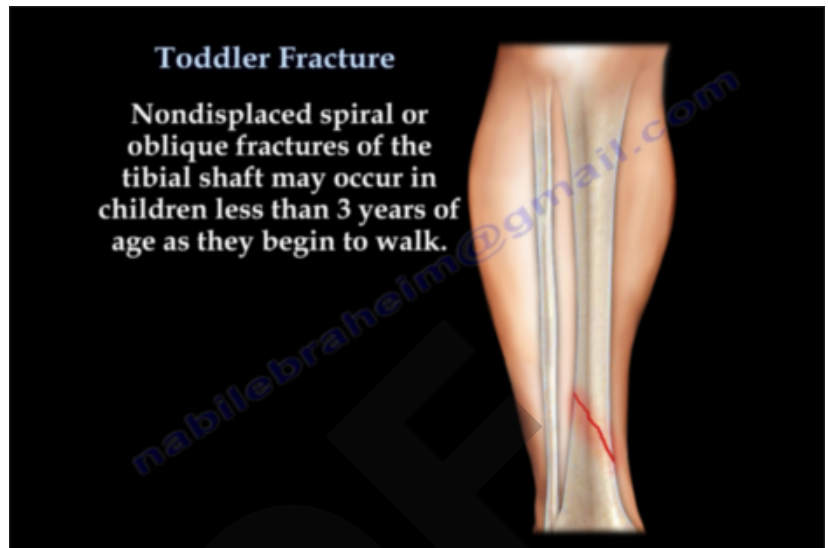should not try to remove warts from the face or genitals. Data shows that half of all warts resolve in a year, while 70% resolve in two years. Patients should avoid any treatment that might produce scarring.

Toddler's Fracture

Nondisplaced spiral or oblique fractures of the tibial shaft may occur in children less than 3 years of age as they begin to walk. In children, the diaphysis of the tibia has a great amount of woven bone (soft or weak bone) rather than osteon bone (hard cortical bone). A thick periosteum prevents displacement of the fracture. This fracture occurs mostly with twists and falls and usually has a rotational component. It usually involves the tibia. This fracture is typically a low energy fracture of the distal tibia. The differential diagnosis of this fracture includes child abuse, osteomyelitis and transient synovitis. The child is usually limping and cannot walk without pain in the leg.

Initial x-rays are usually normal and after 1-2 weeks, a callus develops. New bone formation is an indication of an occult fracture. The doctor will need to look for bowing on the fibula on the x-ray. If a toddler fracture is suspected, it is better to get internal oblique x-rays to confirm this. If the x-ray results are negative, proceed to get a bone scan. Bone scans are usually not needed, but they help in consoling the family. In order to treat a toddler fracture, you need to first rule out constitutional signs.

A cast will be applied and taken off in three to four weeks. You should see the patient 1-2 weeks after putting on the cast. Ultrasounds are useful in diagnosing toddler fractures in the emergency room. Ultrasound can detect a fracture hematoma or changes in the periosteum. This diagnostic modality may become

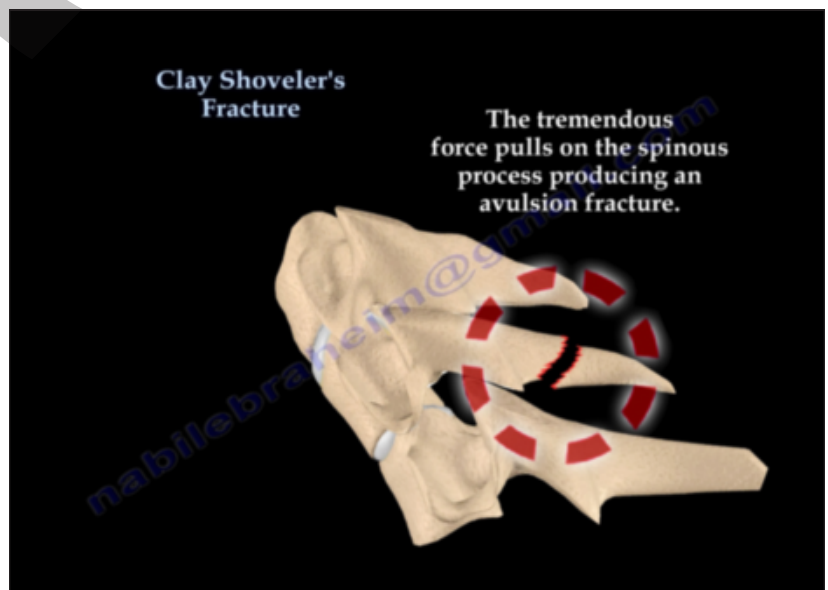


popular in the future. Some physicians recommend using a long leg cast on children with a history of acute injury. These children are unable to walk and have a painful limp. They also have negative x-rays. Before applying the cast, check to see that there are no constitutional signs.

Clay Shoveler's Fracture

Clay shoveler's fracture is a stable fracture through the spinous process of the vertebra C6-T1 and typically occurs at the level of C6 or C7. Clay shoveler's fracture gets its name from the injury suffered by men digging deep ditches in Australia during the 1930s. Powerful hyperflexion of the neck combined with contraction of the paraspinal muscles during shoveling is the typical mechanism of injury. The tremendous force pulls on the spinous process producing an avulsion fracture.

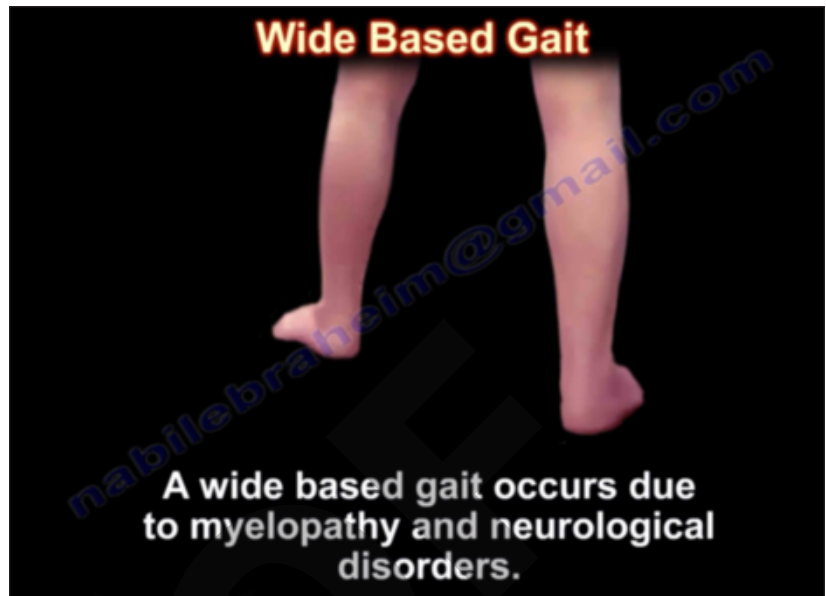This fracture type is best seen on the lateral view x-ray. There will be a ghost sign on AP view x-rays (double spinal process of C6 or C7 resulting from displaced fractured spinous process). Stable fractures can be treated non-operatively, utilizing a collar and physical therapy.



Widebased Gait Myelopathy

What is widebased gait? A widebased gait occurs due to myelopathy and neurological disorders. This gait disturbance is described as clumsy, staggering movements. The patient will have a slow, wide, broad based ataxic gait. Look for associated cervical or thoracic spine pathology. Pathologic long tract signs with upper motor lesion findings may be seen such as Babinski, Clonus, and Hyperreflexia.

The distance between the feet is the normal base width measured during double stance or double support and the width is usually 2-4 inches. With the examiner standing behind the patient, the wide base can be found. The examiner may ask the patient if they have a staggering of their gait. Impaired coordination and balance will widen the base to greater than 2-4 inches. The patient will have a wide stance as they try to maintain balance. There will be unsteadiness of the trunk with excessive shift in the center of gravity.

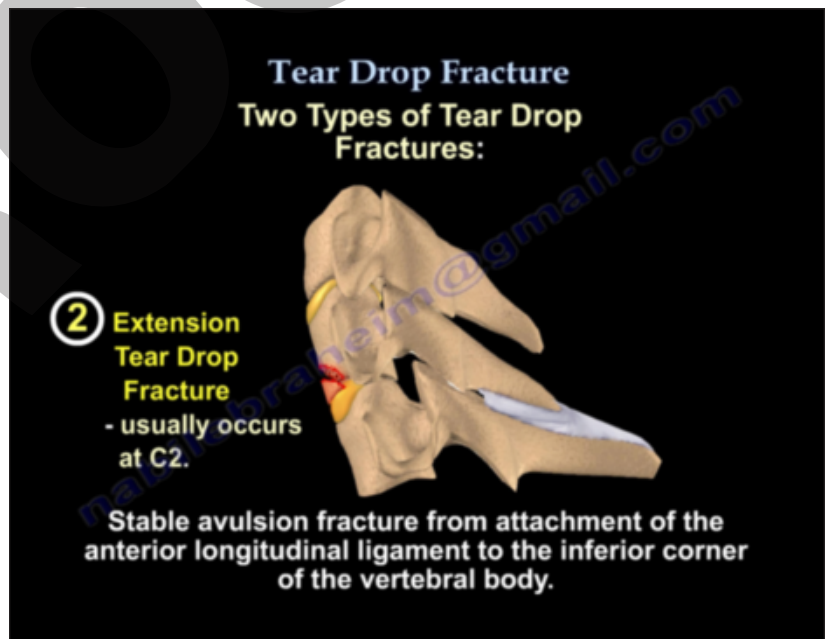


Tear Drop Fracture

There are two types of tear drop fractures: 1.) Flexion tear drop fracture (interspinous ligament tear) 2.) Extension tear drop fracture (disruption of the anterior longitudinal ligament). Both fracture types involve the anterior-inferior aspect of the vertebral body.

The flexion tear drop fracture is the most severe; unstable fracture of the cervical spine. This type of fracture usually occurs from flexion and compression. The flexion tear drop fractures typically affect C5-C6. These fracture types are severe flexion injuries of the cervical spine along with axial loading (compression). This injury may occur for example from diving head first into shallow water. A flexion tear drop fracture is usually associated with spinal cord injury. There will be displacement of the posterior part of the vertebral body into the spinal canal. Separation of the spinous processes will be seen due to disruption of the posterior ligaments. The fracture is unstable and will require surgery. It is best seen in the lateral view x-ray.

The extension tear drop fracture is a stable avulsion fracture from attachment of the anterior longitudinal ligament to the inferior corner of the vertebral body. There is no widening of the posterior elements or posterior vertebral body displacement. This fracture occurs due to a sudden pull of the anterior longitudinal ligament on the anterior inferior aspect of the vertebral body. Extension tear drop fractures occur in extreme



hyperextension of the neck and usually involve C2. There is no spinal cord injury and surgery is not needed. It is best seen on lateral view x-rays. The rest of the vertebrae architecture will be normal except for some paravertebral soft tissue swelling.



THE UNIVERSITY OF TOLEDO
MEDICAL CENTER

Department of Orthopaedic Surgery
The University of Toledo
3000 Arlington Ave.
Toledo, Ohio 43614

Non-Profit
Organization
U.S. POSTAGE
PAID
Toledo, OH
Permit No. 161



2014 Match Day Results

The University of Toledo Medical Center's Department of Orthopaedic Surgery Residency Program took part in Match Day at Noon on Friday, March 21, 2014. Every year on Match Day, the residency program placement results of the National Resident Matching Program are revealed to participating graduating medical students across the country.

The following medical students were matched to the Orthopaedic Residency Program for 2014: Justin Lea (University of Toledo College of Medicine), Jacob Azurdia (University of Vermont College of Medicine), Anthony Kouri (Loyola University Chicago Stritch School of Medicine), and Mark Oliver (Indiana University School of Medicine).

We are delighted to have them join the program in June 2014.

The Orthopaedic Residency Program is a five-year program fully accredited by the Accreditation Council for Graduate Medical Education (ACGME).

THE UNIVERSITY OF TOLEDO MEDICAL CENTER
**ORTHOPAEDIC
MONTHLY**

Editors:

Dr. Nabil Ebraheim,
department chairman
and professor of orthopaedics,
and **Amanda Kaverman**,
assistant to the chairman.

Neither Dr. Ebraheim nor
Amanda Kaverman have any
relationships with industry to
disclose.

**Department of
Orthopaedic Surgery**
The University of Toledo
3000 Arlington Ave.
Toledo, Ohio 43614

For appointments, call
419.383.3761.