



THE UNIVERSITY OF TOLEDO MEDICAL CENTER

# ORTHOPAEDIC MONTHLY

VOLUME 4, ISSUE 3 JULY 2011

## Orthopaedic Center to Host Forums for the Community

*An Editorial by Dr. Nabil Ebraheim, Chairman and Professor*

In an effort to better educate the community about orthopaedic injuries and conditions, the Orthopaedic Center will be hosting monthly public forums focusing on different topics.

In May and June, the Orthopaedic Center held its first two public forums focusing on low back pain and sports medicine. UTMC's spine surgery team, represented by Dr. Hossein Elgafy and Dr. Mustafa Khan, were on hand to provide a short lecture, answer questions, and read/explain x-ray and MRIs patients brought with them. In June, Dr. Jason Levine and Dr. David Sohn provided a short lecture and answered questions related to sports medicine.

In the coming months, the Orthopaedic Center will host a variety of public forums for the community with topics including: joint replacement, sports medicine, hand conditions, foot and ankle conditions, difficult fractures and spine conditions.

The next public forum is slated for July 26 at 6 pm in the Orthopaedic Center. The topic will be neck and spine pain. Dr. Elgafy and Dr. Kahn will be on hand to answer questions and provide the latest information on neck and spine pain.

Attendees will receive complimentary food and refreshments.

---

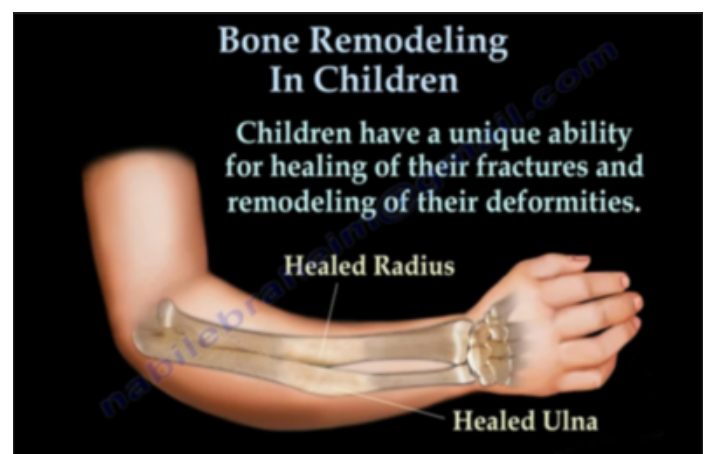## Bone Remodeling in Children

Children's bodies have a unique ability to heal fractures, providing physicians with opportunities in bone remodeling. This should be revised in graphic and caption as well.

Physicians should strive to achieve anatomic reduction of fractures in children. Surgeons may not be able to achieve acceptable reduction every time. These fractures do not always remodel. The deformities may lead to unacceptable results in cosmesis and function.

So what are the rules for remodeling in children? Of first importance is the age of the patient. Younger children tend to have better remodeling potential; therefore, the younger the patient, the better the potential outcome. Children with two or more years of growth left have a chance for remodeling. The periosteum in children is thick and promotes faster healing of the fracture as well as increased potential for remodeling.

Second of importance, revolves around distance of the fracture from the end of the bone. Fractures in the metaphysis remodel better than in the middle of the bone.



*Children have a unique ability for healing of their fracture and remodeling of their deformities.*

*Continued on page 2*

Fractures in the middle of the bone have less potential for remodeling, while fractures in the metaphysis remodel better because they are closer to the growth plate.

Third, severity of angulation affects remodeling in children. If there is minimal angulation, the bone could remodel completely. If angulation is more severe, the bone will only partially remodel. Angulation in the plane of joint movement is most likely to improve with growth and remodeling.

How is the deformity remodeled? Remodeling means correction; therefore, the osteoclasts will resorb bone from one side by eating that bone. The osteoblasts will lay new bone formation. The periosteal will help in this manner and the bone will gradually straighten its shape. Remodeling will not improve displaced fractures involving the joint or the growth plate.

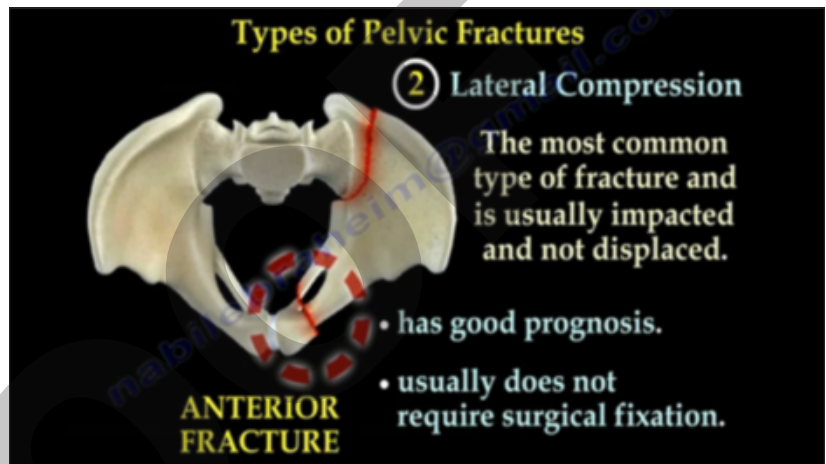
## Pelvic Fractures

To understand pelvic fractures, it's helpful to first look at the anatomy. First, the pelvis contains the sacroiliac joints, which connect the spine to the pelvis. It can be found between the sacrum (the triangular-shaped bone in the lower portion of the spine) and the ilium of the pelvis. Joining these bones together are the strong posterior sacroiliac joint ligaments. The ischium forms the lower and back part of the hip bone. Finally, the pubic symphysis is the midline joint uniting the superior rami of the left and right pubic bones.

The sacroiliac joint has strong posterior ligaments. The stability of the pelvis depends on the integrity of the posterior weight-bearing sacroiliac joint complex. The transfer of weight bearing forces from the spine to the lower extremities occurs through the sacroiliac joint.

The pelvis is a ring. When a force occurs, it will injure the ring in the front (anterior) and in the back (posterior). Anterior injuries are usually obvious and will be noted on radiographs; they are usually associated with posterior injuries or fractures. Posterior injuries could be occult. Physicians should always look at the back of the pelvis. An unstable pelvis will have a gap or a comminution. Posterior fractures are serious. They will need a significant blood transfusion and surgery. The outcomes for posterior fractures are unpredictable. Posterior fractures with disruption of the posterior ring complex are serious injuries as they lead to instability of the pelvis and can cause profuse bleeding. The resultant instability, if not fixed surgically, can cause late deformity, limb length discrepancy and pain.

There are three types of pelvis fractures: anteroposterior compression fractures, lateral compression fractures, and vertical shear fractures. Anteroposterior compression fractures can either be with a pubic rami fracture or it can be with an open book type where the symphysis pubis opens up. We call this symphysis pubis diastasis. Treatment includes: closing the book, pelvic binder/sling, or surgery



*Lateral compression fractures are the most common type of fractures and are usually impacted, not displaced.*

if the symphysis pubis diastasis is more than 2.5 cm. Surgery can be done through an external fixator or plate.

Lateral compression fractures are the most common type of fractures and are usually impacted, not displaced. These fractures have a good prognosis and do not usually require surgical fixation.

Vertical shear fractures are the third type of pelvic fractures. These fractures are bad and require surgery, both anteriorly and posteriorly. In addition, they require extensive blood transfusions. The outcome is guarded and initial external fixation may be needed to control bleeding. Traction may be used in the emergency room, which will reduce the vertical displacement and reduce motion at the fracture site. Pelvic binders may also be used in the emergency room. Vertical shear fracture are stabilized surgically anterior and posteriorly. Anterior stabilization uses internal fixation with plates. Reduction of the symphysis pubis is done before fixation. Usually, these fractures will need to be fixed posteriorly. Here, we use posterior screw fixation.

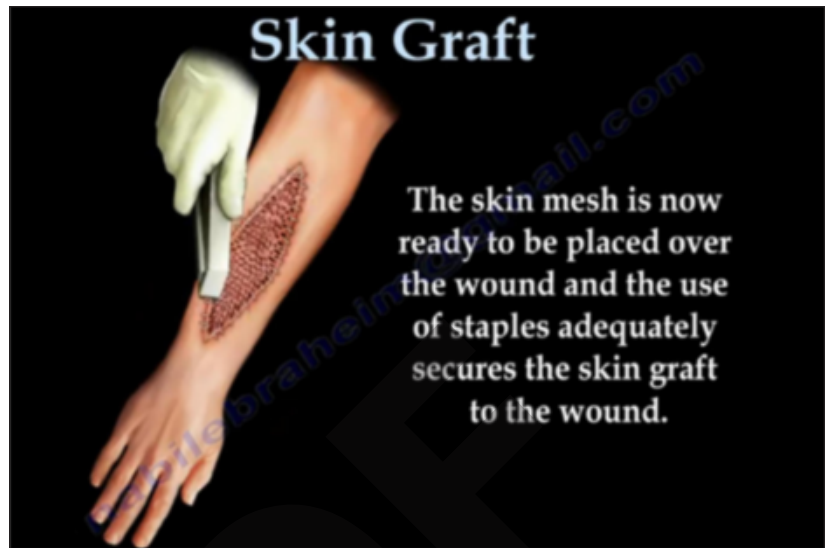# Skin Grafts

A skin graft refers to a thin slice of healthy skin that is transplanted from one area of the patient's body to the area that is injured or damaged. Skin grafting does not affect the function of the limb.

Skin grafts are usually needed for a variety of different injuries. Wounds that require skin grafting can occur from trauma, infection or surgery. High energy fractures may cause compartment syndrome which require a fasciotomy. In compound fractures, the open wound is most often treated with a skin graft.

In simple, uncomplicated wounds, the surgeon can usually close the wound with sutures or staples. Occasionally, the wound is large and the surgeon cannot approximate the ends. In these cases, a skin graft is necessary. Wounds are initially treated with wet or dry dressing. The wound VAC (vacuum-assisted closure) system is also used to promote healing and reduce swelling of the open wound.

Prior to the skin graft being harvest and applied, the wound should be debrided, excised and measured. The jet lavage is commonly used to thoroughly cleanse the wound. A skin graft involves cutting a thin slice of skin from the donor area. The skin sample is commonly taken from the area of the thigh, but can also be taken from the arms and gluteal regions. The donor skin is meshed, which will cut tiny slits in the graft, allowing the graft to be stretched for covering large areas of the wound, using less skin. The skin graft is then placed over the wound with staples to adequately secure the skin graft.



*A skin graft refers to a thin slice of healthy skin that is transplanted from one area of the patient's body to the area that is injured or damaged*

Skin grafts are very fragile and great care should be taken when looking after them even after the wound has healed. Therefore, sterile dressings are applied to the wounds and should remain in place for approximately five days without being touched. During the first dressing change (after the fifth day), the clinician will slowly remove the bandages and saline may be used to moisten the dressings in order to avoid damaging the graft. During this time, the wound is inspected for signs of infection.

# Cat Scratch Disease

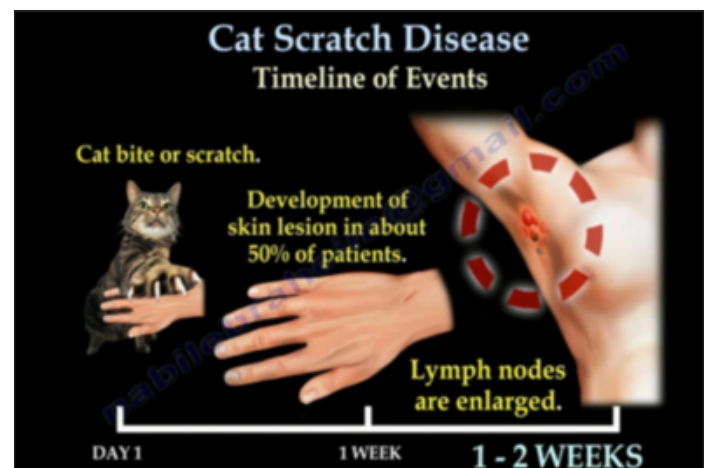Cat scratch disease is an infection transmitted by cat scratches and bites. The lesion is usually small and less than 1 cm in length.

Cat scratch disease is normally a benign, self-limiting illness which lasts for about 6-12 weeks. It is caused by exposure to bartonella henselae bacteria.

Scratches or bites from an infected cat can cause the following symptoms:

- Swollen or draining lymph nodes
- Fever
- Fatigue
- Headaches

Swollen, tender or hard lymph nodes could be confused with a soft tissue tumor. These areas of lymph node concentration include:



*Timeline for Cat Scratch Disease*

cervical nodes, axillary nodes, cubital (epitrochlear) nodes, and inguinal nodes.

*Continued on back page*



THE UNIVERSITY OF TOLEDO  
**MEDICAL CENTER**

Department of Orthopaedic Surgery  
The University of Toledo  
3000 Arlington Ave.  
Toledo, Ohio 43614

---

Non-Profit  
Organization  
U.S. POSTAGE  
PAID  
Toledo, OH  
Permit No. 161

---



*Cat Scratch Disease continued*

The timeline of events for cat scratch begins with a cat bite or scratch. Within one week, there is a development of a skin lesion in about 50 percent of patients. In the first two weeks, there will be noticeably enlarged lymph nodes.

Swollen lymph nodes with no other etiology and a scratch or bite from being in contact with a cat, could suggest the presence of cat scratch disease. Symptoms are self-limiting and can vary from mild to severe, lasting for several weeks. Physicians should check for an elevated sedimentation rate and C-reactive protein (CRP). A positive skin test for cat scratch disease is important for establishing the diagnosis.

Treatment includes: doxycycline, ciprofloxacin, and azithromycin. It is a pseudo-tumor and should be considered in the differential diagnosis of soft tissue lesions. No biopsy is needed. Biopsy will show lymphoid tissue and necrotizing granulomas.

THE UNIVERSITY OF TOLEDO MEDICAL CENTER  
**ORTHOPAEDIC  
MONTHLY**

Editors:

**Dr. Nabil Ebraheim**,  
department chairman  
and professor of orthopaedics,  
and **Dave Kubacki**, assistant  
to the chairman.

Neither Dr. Ebraheim nor Dave  
Kubacki have any relationships  
with industry to disclose.

**Department of  
Orthopaedic Surgery**  
3000 Arlington Ave.  
Toledo, Ohio 43614

For appointments, call  
419.383.3761.