



THE UNIVERSITY OF TOLEDO  
**MEDICAL CENTER**

APPROVED FOR AMA PRA CATEGORY 1 CREDIT: SEE INSERT FOR DETAILS

THE UNIVERSITY OF TOLEDO MEDICAL CENTER

# ORTHOPAEDIC MONTHLY

VOLUME 5, ISSUE 5 MAY 2015

**THE DOCTORS OF TOMORROW:**

## **A Long, Hard, Narrow Road with A Gratifying Result - Part I**

Editorial by Dr. Nabil Ebraheim, Chairman and Professor of Orthopaedics, Residency Program Director

The road to becoming an orthopaedic surgeon is long and difficult. For medical students interested in orthopaedics, the road can be even more difficult, as it is among the most competitive of specialties.

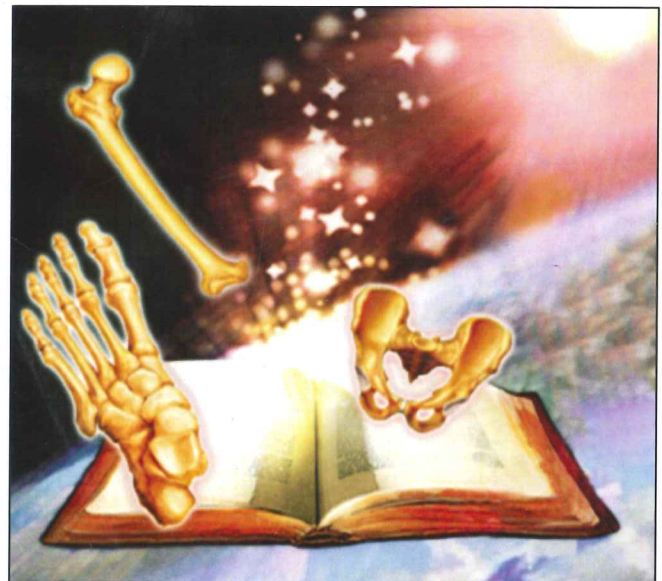Following college, future doctors head to medical school for four years. With some of the best and brightest students applying, it's very difficult to gain acceptance into medical school. In addition, the whole process is very expensive. The students and/or families need to take out loans. They learn the importance of tightening their belts and making sacrifices.

After medical school is completed, students enter residency. The sacrifices continue as they take calls, delay time with their families and delay having kids or spending time with their children. By the end of residency, they learn and refine their skills in a specific sub-specialty.

Finally, they become independent orthopaedic surgeons. They begin to realize there are struggles at this level as well. They have to worry about health-care regulations, research regulations, and patient needs. In addition, they have to worry about the business aspect of their practices and systems. As soon as they solve one problem, they are on to the next problem.

All of this may sound negative, but it usually does not deter anyone from going to medical school. More and more people are applying to the medical school. Why? Because being a doctor is the best profession. We are blessed with a special gift and talent, which we are able to use for the betterment of mankind. Patients come to us to ease their pain and suffering. To be given that opportunity is rare.

There will always be people second-guessing our treatment decisions, our handling of matters, our working hours and our lifestyle, but that comes with the job. We are fortunate to have this opportunity as doctors. Millions and millions of people want to be in that position,



but they cannot. Whether you are a medical student, resident, fellow or doctor, you are fortunate to be in that position; you should be proud of yourself and your profession. You should all get up in the morning with smiles on your faces and a sense of purpose. For where there is a pulse, there is a purpose.

Our specific residency program has selected some of the brightest and most intelligent students for the forthcoming year. We are delighted to have 4 Alpha Omega Alpha honor students for our orthopaedic residency program. I am thankful for the opportunity to make a positive impact in the lives of my patients and am thankful we have the opportunity to participate in teaching the doctors and orthopaedic surgeons of tomorrow. What a great feeling!

## **Virchow's Triad, DVT and Blood Clots**

Deep venous thrombosis or blood clots form in the deep veins usually in the legs. Although deep venous thrombosis (DVT)

predominantly occurs within the deep veins in the legs, it may also occur in the upper extremities. The deep veins pass through the deep

*Continued on page 2*



*Virchow's Triad, DVT and Blood Clots continued*

tissues and the muscles. Muscle contractions (walking, running, activity, etc.) squeeze blood through the deep veins to the heart. The deep veins have valves which prevent the blood from flowing back to the feet and ankles.

DVT is the formation of a blood clot (thrombus) within a deep vein. The majority of blood clots that form are small and they are usually broken down or dissolved. Large clots may form and can block the vein causing the patient to complain of pain and swelling. The clot may detach partially or totally (embolism). Some of the clots may be silent and show no symptoms. The detached blood clot may travel from the deep veins to the heart and then finally lodges itself in the pulmonary artery of the lungs, causing permanent damage to the lungs. In some cases, the clot will pass through the heart to the aorta and create emboli in the brain (patent foramen ovale).

VIRCHOW'S TRIAD – contributes to the development of deep venous thrombosis. One of the triad may contribute more than the others. Platelet dysfunction is not part of the Virchow's Triad.

1. Endothelial injury. Endothelial injury is secondary to injury or surgery. Induces thrombosis. May occur due to manipulation of fractures, dislocation, or from placement of retractors or pressure on the tissues.
2. Venous Stasis. Will lead to platelet contact with the endothelial lining such as with use of a tourniquet. Hypotension, or with knee flexion during surgery. It occurs with impaired mobility in the elderly.

Immobility will cause the venous circulation to slow down and the clotting factors in the blood to clump together, ultimately leading to DVT.

In my opinion, the most important factor to prevent blood clots is maintaining the patient's mobility. It is important to get the patient up out of bed and moving around when possible either on their own or with crutches. THIS IS A SIMPLE PREVENTATIVE STEP.

3. Hypercoagulability: Tissue debridement, collagen, fibrinogen, tissue thromboplastin. Blood diseases such as Protein S and Protein C deficiency. Abnormality in Factor V Leiden.

RISK FACTOR FOR THROMBOEMBOLISM: History of previous thromboembolism, Obesity, Malignant disease, Immobilization, Pregnancy, Old age, History of congestive heart failure, Oral contraceptives, Genetic blood diseases (genetic hypercoagulable state),

Major orthopaedic procedure: Up to 60% of asymptomatic DVT in total joint arthroplasty without prophylaxis. Up to 20% of symptomatic DVT without prophylaxis. Proximal DVT in about 15 – 25%. Fatal pulmonary embolism up to .05%.

Total Knee Arthroplasty: High risk of DVT. Low risk of pulmonary embolism.

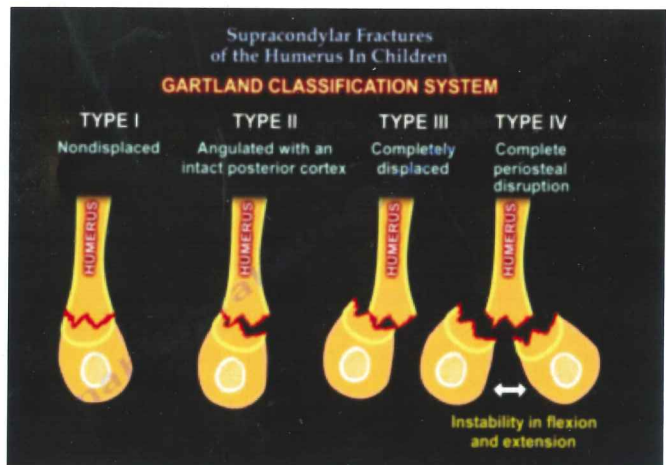
When giving prophylaxis, balance the risk of clotting with the risk of bleeding.

## Supracondylar Fractures of the Humerus in Children

Supracondylar fractures constitute approximately 50% of all elbow fractures. The supracondylar region is thin and weak and thus it can fracture easily.

FRACTURE TYPES: The fracture can be an extension type, or an flexion type. 1) The first type is an Extension Type fracture. This is the most common type (95%). It occurs due to falling onto an outstretched hand. In this type of fracture, the distal fragment displaces posteriorly. Anterior interosseous neurapraxia is the most common nerve palsy occurring with the supracondylar fracture. Injury to the anterior interosseous nerve will lead to weakness of the flexor digitorum profundus muscle to the index finger and the flexor pollicis longus muscle.

The patient will not be able to do the 'OK' sign with his hand or bend the tip of his index finger. Radial nerve neuropraxia is the second most common palsy and is evident by weakness in wrist and finger extension. 2) The second type of fracture is a Flexion Type Fracture, which is rare and occurs due to falling directly on a flexed elbow. In this type of fracture the distal fragment is displaced anteriorly and may be accompanied with ulnar nerve neurapraxia. Injury of the Ulnar nerve will lead to loss of sensation along the little finger. Later on, the patient may also develop weakness of the intrinsic hand muscles and clawing.



GARTLAND'S CLASSIFICATION OF SUPRACONDYLAR FRACTURES: Gartland's Type I fracture is a Nondisplaced fracture. A Type II fracture is Angulated with an intact posterior cortex. A Type III is a fracture showing Complete displacement. A Type IV has Complete periosteal disruption and shows instability in both flexion and extension.

*Continued on page 3*

*SUPRACONDYLAR FRACTURES IN HUMERUS continued*

**RADIOLOGY** – Plain AP and lateral x-rays should be obtained. A posterior fat pad sign seen on a lateral view x-ray should increase your suspicion of an occult fracture around the elbow. The **ANTERIOR HUMERAL LINE**: On a lateral view x-ray, the anterior humeral line is drawn along the anterior border of the distal humerus. Normally, the anterior humeral line should run through the middle third of the capitellum. In extension type fractures the capitellum will be displaced posteriorly relative to the anterior humeral line.

**BAUMANN'S ANGLE**: Baumann's Angle is formed by a line perpendicular to the axis of the humerus and a line going through the physis of the capitellum. Normally, Baumann's angle should measure at least 11 degrees (variable).

On examination, it is very important to assess the neurovascular structures. The Anterior interosseous nerve is assessed by asking the patient to do the OK sign with his hand. The Radial nerve is assessed by asking the patient to extend the wrist and fingers. The Ulnar nerve is initially assessed by loss of sensation along the little finger. Later on, the patient may also have weakness of the intrinsic hand muscles and clawing.

**TREATMENT**: Non-operative treatment is usually indicated for Type I fractures, and consists of splinting or casting the elbow for a duration of 3-4 weeks. It is very important to remember not to flex the elbow in a splint or cast beyond 90 degrees in order to avoid vascular compromise and compartment syndrome.

Operative treatment is often recommended for Type II and III fractures, which are usually treated by closed reduction and percutaneous pinning. During reduction, pronation of the forearm during elbow flexion helps to correct a varus deformity. After reduction, check for a gap in the fracture. The neurovascular bundle

may be trapped there. Free the brachialis muscle from the fracture site if it is interpositioned there. Fixation of the fracture is usually achieved with 2-3 divergent lateral pins, depending on stability. Medial pins may also be added depending on stability. You must be aware of the Ulnar nerve when placing the medial pin.

**OPERATIVE TREATMENT**: Open reduction is indicated only when closed techniques are unable to achieve appropriate reduction of the fracture. Avoid posterior dissection to preserve vascularity of the fractured segment. Fracture reduction and fixation should be done emergently in cases of vascular compromise.

**COMPLICATIONS**: Neurapraxia is one of the complications that may occur. It resolves by itself and is thus observed only. A Cubitus varus deformity may occur due to malunion of the fracture. It only presents a cosmetic problem since it does not affect function. This deformity can be corrected later on by a supracondylar valgus osteotomy. Vascular problems such as compartment syndrome may occur. Volkmann's Ischemic Contracture may occur due to compression of the brachial artery when the patient is placed in a cast in hyperflexion (more than 90 degrees).

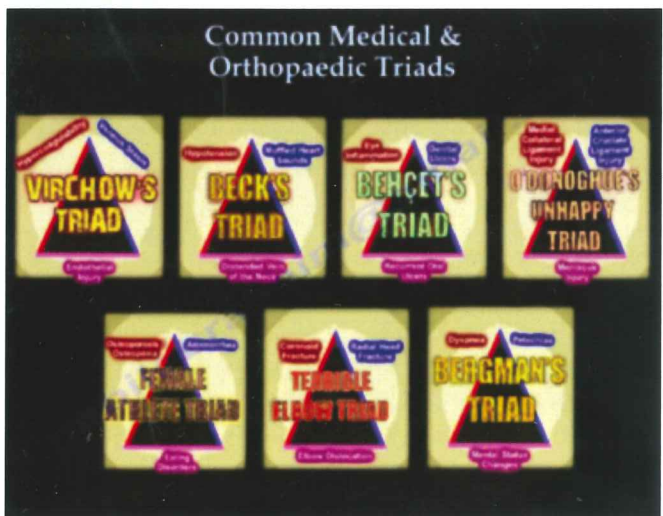
**IMPORTANT SCENARIOS**: A patient may present with a Displaced Type III fracture containing a pulseless hand. Or, he may have adequate circulation which is evident by a normal temperature and color of the hand. Or, he may have inadequate circulation which is evident by a blue and cold hand. In both cases Urgent Closed Reduction and Percutaneous Pinning is required. After closed reduction and percutaneous pinning, if the circulation is adequate observe the patient and place in a splint that is 45 degrees. However, if a patient continues to have inadequate circulation after closed reduction and percutaneous pinning then the patient will require vascular exploration and repair.

## Common Medical & Orthopaedic Triads

There are three factors that are thought to contribute to deep Venous Thrombosis: 1. Endothelial injury: damage to the inner lining of blood vessels (endothelium). 2. Venous Stasis: a condition of slow blood flow in the veins, usually in the legs. 3. Hypercoagulability: refers to an increased risk of thrombosis (blood clots). Guess the Triad: **VIRCHOW'S TRIAD**.

There are three factors that are associated with acute cardiac tamponade. 1. Distended vein of the neck: increased Jugular Vein Distention (JVD) 2. Muffled Heart Sounds: Heart sounds become muffled and distant because of the insulating effects of fluid in the pericardial sac. 3. Hypotension: Low blood pressure. Guess the Triad: **BECK'S TRIAD**.

There are three interrelated factors that are a health concern for active females who are driven to excel in sports: 1. Eating disorders: restrictions in the diet cause an imbalance of energy. 2. Amenorrhea: (absence of a menstrual period). Eating disorders affect the brain's regulation of the ovaries. 3. Osteoporosis/Osteopenia: Loss of exposure of estrogen will lead to osteoporosis. Osteoporosis will lead

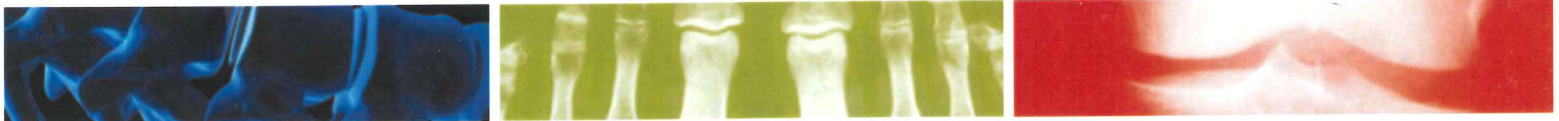

to bone fragility and stress fractures. Guess the Triad: **FEMALE ATHLETE TRIAD**.



THE UNIVERSITY OF TOLEDO  
**MEDICAL CENTER**

Department of Orthopaedic Surgery  
The University of Toledo  
3000 Arlington Ave., MS 1094  
Toledo, Ohio 43614



*Common medical triads continued*

There are three associated factors with this triad that commonly occur due to a fall onto an outstretched hand: 1. Elbow Dislocation. 2. Unstable Radial Head Fracture (radius). 3. Type III Coronoid Fracture (ulna). Guess the Triad: TERRIBLE ELBOW TRIAD.

There are three associated factors with this triad that can cause a wide range of symptoms, although it is rare for someone with the condition to have all of them at once: 1. Recurrent Oral Ulcers: raised, round lesions in the mouth that quickly turn into painful ulcers. 2. Genital Ulcers: they commonly occur on the scrotum or the vulva. 3. Eye inflammation (Uveitis). Guess the Triad: BEHCET'S TRIAD.

There are three associated injuries with this triad. This usually occurs in sports, typically with a non-contact pivoting injury: 1. Meniscus Injury: Tear of the Lateral meniscus. 2. Anterior Cruciate Ligament Injury: ACL tear. 3. Medial Collateral Ligament Injury: MCL tear. Guess the Triad: O'DONOGHUE'S UNHAPPY TRIAD.

There are three associated factors with this triad and it is often seen when a patient suffers a fat embolism: 1. Mental Status Changes...in brain function, such as confusion, amnesia (memory loss). 2. Petechiae: pinpoint, round spots that appear on the skin as a result of bleeding. 3. Dyspnea: Difficult, labored breathing or shortness of breath. Guess the Triad: BERGMAN'S TRIAD.

See Dr. Nabil Ebraheim's YouTube video on Common Medical & Orthopaedic Triads:

<https://www.youtube.com/watch?v=LmMUO1g7muM>

THE UNIVERSITY OF TOLEDO MEDICAL CENTER

## ORTHOPAEDIC MONTHLY

Editors:

**Dr. Nabil Ebraheim**, Professor  
and Department Chairman of  
Orthopaedic Surgery;

**Suzanne Payne**  
**Amanda Ferguson**

Dr. Ebraheim, Amanda Ferguson and  
Suzanne Payne do not have any  
Relationships with industry to disclose.

**Department of  
Orthopaedic Surgery**  
The University of Toledo  
3000 Arlington Ave., MS 1094  
Toledo, Ohio 43614

For appointments, call  
419.383.3761