



THE UNIVERSITY OF TOLEDO MEDICAL CENTER **ORTHOPAEDIC MONTHLY**

VOLUME 4, ISSUE 6 OCTOBER 2014

Plantar Fascia Rupture

Plantar fascia rupture is an uncommon injury that is characteristic of acute pain in the arch of the foot. Rupture is often associated with long-standing flat feet deformity or can occur from steroid injections.

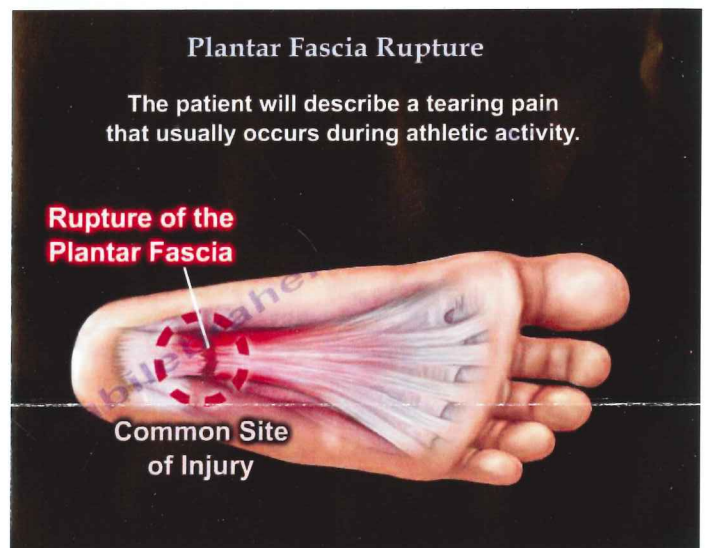Anatomy

- The plantar fascia is formed by three bands – Medial, Central and Lateral.
- The plantar aponeurosis is the central part of the plantar fascia.
- The plantar fascia is inserted into the medial tuberosity of the calcaneus and extends distally, becoming broader and thinner.

The plantar fascia acts as a bow string. It is a dynamic stabilizer of the longitudinal arch of the foot. When the plantar fascia tears, the patient will describe a tearing pain that usually occurs during athletic activity. Walking will be very difficult with tenderness, swelling and significant bruising on the sole of the foot. Some patients may have a noticeable tightness of the calf muscle (equinus contracture) in association with rupture of the plantar fascia.

Rupture of the plantar fascia may be partial or complete and an MRI will identify the rupture. Rupture is often in the arch of the foot opposed to where the plantar fascia inserts into the heel (calcaneus). Ultrasound has the same accuracy as an MRI for imaging of the plantar fascia. Ultrasound interpretation of the plantar fascia rupture may be difficult. You may need dynamic maneuvers with dorsal flexion of the forefoot to stretch the plantar fascia. Usually, the proximal part of the plantar aponeurosis is clearly visualized on the ultrasound. An MRI is probably better in diagnosing a plantar fascia rupture.

Treatment of Plantar Fascia Rupture



- Non-weight bearing for 2-3 weeks.
 - Walking boot.
 - Crutches.
 - Physical therapy.
 - Surgical treatment could be used in some athletes who continue to have pain despite a well conducted conservative treatment.
 - Surgery is done to release the fascia and to excise the scar tissue.
- Patients suffering from rupture of the plantar fascia typically achieve favorable outcomes with return to activity.

Tennis Elbow Muscle ECRB

The muscle that is involved in the condition of tennis elbow is the Extensor Carpi Radialis Brevis (ECRB) muscle. The ECRB muscle originates from the lateral epicondyle of the humerus (common extensor tendon). The ECRB muscle is inserted into the base of the dorsal aspect of the 3rd metacarpal. This muscle gets its nerve supply from the radial nerve. The function of the muscle is to extend and abduct the hand at the wrist joint.

The ECRB is located in the 2nd dorsal compartment on the radial side of the lister's tubercle.

Conditions that are associated with this muscle are: tennis elbow, intersection syndrome, ECRB muscle, wrist drop.

Continued on page 2

Tennis elbow (lateral epicondylitis) is an overuse injury that causes inflammation, tendinosis, and lateral elbow pain at the origin of the ECRB tendon.

The pathology of the ECRB tendon in tennis elbow shows disorganized collagen, vascular hyperplasia and fibroblast hypertrophy. Treatment usually consists of rest, stretching exercises followed by strengthening exercises. Steroid injections may also be given locally in order to break the cycle of inflammation. Surgery is usually left as a last resort.

The pain from intersection syndrome is felt on the top of the forearm, where two muscles that connect to the thumb cross over the underlying wrist tendons. Inflammation occurs where the Extensor carpi radialis longus and brevis intersect with the abductor pollicis longus and extensor pollicis brevis.

The ECRB muscle is important in dorsal approach to the radius.

The Thompson dorsal approach to the proximal radius may be used for exposure of the posterior aspect of the radial shaft. The incision is made between the two muscles of the ECRB and the Extensor Digitorum.

In tennis elbow surgery, excessive release of the tendon (ECRB) and the lateral side of the elbow can cause elbow instability. Excessive release of the ECRB tendon (the origin) during tennis elbow surgery can cause injury to the ulnar humeral collateral ligament and elbow instability. Please note the proximity of the origin of the ECRB tendon to the ulnar humeral collateral ligament. The ligament is close to the tendon and can be injured due to excessive release.

In radial nerve palsy, injury to the radial nerve results in wrist drop due to paralysis of the wrist extensors. The pronator teres transfer to the ECRB is a very popular tendon transfer in high radial nerve palsy used to restore wrist extension.

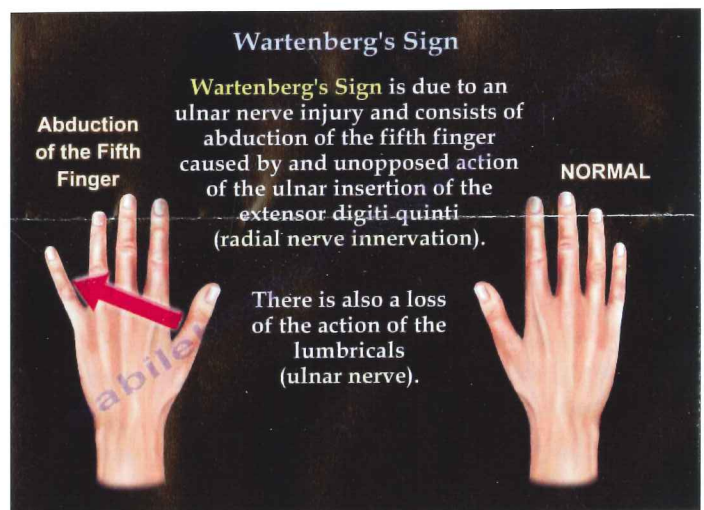
Wartenberg's Sign

Wartenberg's sign is an indication of ulnar nerve palsy. There is a difference between Wartenberg's Sign and Wartenberg's Syndrome.

Wartenberg's Sign is due to an ulnar nerve injury and consists of abduction of the fifth finger caused by an unopposed action of the ulnar insertion of the extensor digiti quinti (radial nerve innervation). There is also a loss of the action of the lumbricals (ulnar nerve). Wartenberg's Sign occurs due to paralysis of the palmar interosseous muscle that adducts the little finger. The unopposed action of the extensor digiti quinti causes the finger to rest in a more abducted position.

With Wartenberg's syndrome, the nerve is likely to become compressed between the Brachioradialis and the ECRL tendons, especially during forearm pronation. Wartenberg's Syndrome is caused by entrapment of the superficial branch of the radial nerve at this point where the nerve arises from beneath the muscles. There will be altered sensation associated with Wartenberg's syndrome due to entrapment of the superficial branch of the radial nerve.

The difference between Wartenberg's Sign and Wartenberg's Syndrome is:



1. Wartenberg's Sign is the abduction of the fifth finger. Ulnar Nerve injury causes abduction of the Fifth Finger.
2. In Wartenberg's Syndrome, the Radial Nerve entrapment causes altered sensation on the back of the hand.

Conditions Affecting Dorsal Wrist Compartments

There are 6 compartments in the dorsal aspect of the wrist, each containing one or more tendons.

Compartment one contains the Abductor pollicis longus and extensor pollicis brevis tendons. These two tendons are involved in the condition of DeQuervain's syndrome. DeQuervain's Syndrome is

inflammation of the sheath or tunnel that surrounds the two tendons that control movement of the thumb. There is pain and swelling over the thumb side of the wrist and difficulty gripping. Activities that may cause this syndrome include: twisting/wringing out wet towels, hammering, skiing, lifting heavy objects, and holding or carrying babies and young children.

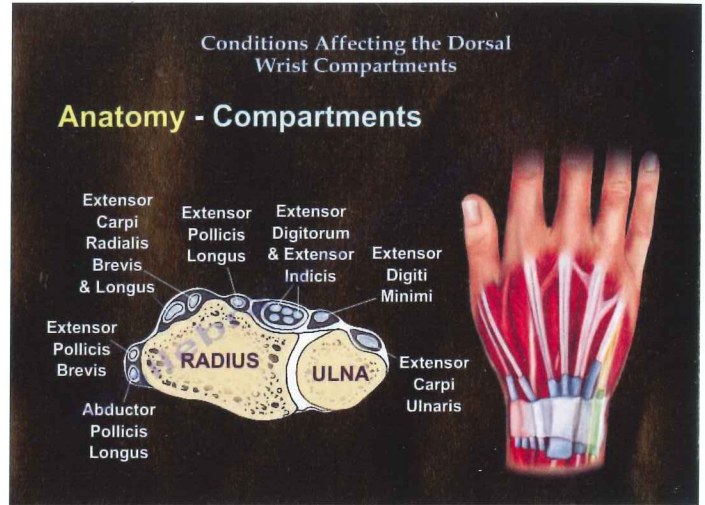
Finkelstein's test is used to diagnose DeQuervain's tenosynovitis in patients who have wrist pain. The Finkelstein test is conducted by making a fist with the fingers closed over the thumb and the wrist is bent toward the little finger. The wrist is then pulled so that the tendons of the first dorsal compartment are stretched distally, causing sharp, local pain if tendon inflammation is present.

Compartment two contains the extensor carpi radialis brevis & longus tendons. These two tendons are involved in the condition of intersection syndrome. The pain from intersection syndrome is felt on the top of the forearm, where two muscles that connect to the thumb cross over the underlying wrist tendons (Inflammation of the extensor carpi radialis longus and extensor carpi radialis brevis as they intersect with the abductor pollicis longus and the extensor pollicis brevis). Activities and motions that may cause intersection syndrome include: overuse of the wrist and hand, grasping, turning, twisting.

The extensor pollicis longus tendon is contained in compartment three. This tendon is involved in the condition of drummer's wrist. Drummer's wrist is inflammation of the extensor pollicis longus tendon that runs along the back of the wrist. Musicians playing in a band or orchestra who play for long periods of time without rest may suffer from this condition. Mild cases can be treated with rest, splinting, and non-steroidal anti-inflammatory medication.

Extensor digitorum & extensor indicis tendons are involved in the condition of extensor tenosynovitis. These tendons are found in compartment four. Extensor tenosynovitis is irritation of the tendons located in the fourth extensor compartment.

The extensor digiti minimi is involved in the condition of Vaughn Jackson syndrome. This tendon is located in compartment five. Vaughn Jackson syndrome is the disruption of the extensor tendons.



It is a progressive rupture beginning on the ulnar side of the hand and wrist with the extensor digiti minimi and continuing radially. The tendons become frayed and disrupted. Attrition occurs over the bony prominence of the distal ulnar head.

The extensor carpi ulnaris tendon is involved in the condition of snapping extensor carpi ulnaris (ECU). Snapping ECU syndrome is a condition due to the extensor carpi ulnaris tendon sliding in and out of its groove. It involved hypersupination/ ulnar deviation injury. The snap of the tendon with supination occurs with ulnar deviation and can fell the tendon snap out of the groove. If the ECU tendon is not held in place, it may 'snap' over the bone as the wrist is rotated causing tendonitis of the ECU tendon. Fifty percent (50%) of snapping ECU's are associated with TFCC tears. The muscle is an important muscle although its name suggests it is small and not important.

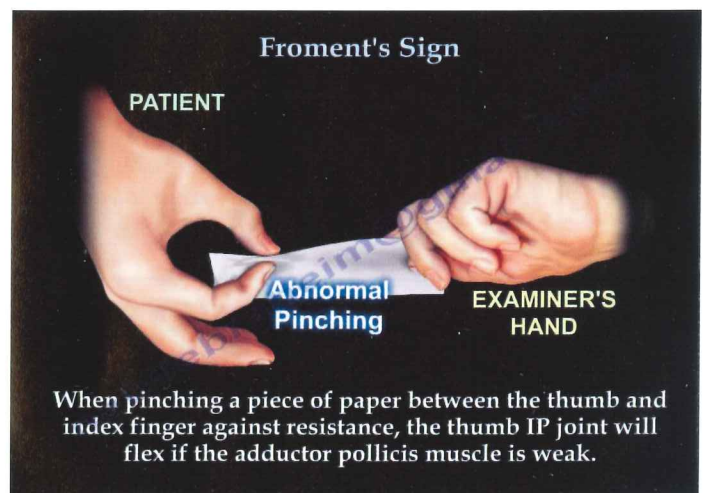
Froment's Sign

The Froment's Sign occurs due to weakness of the adductor pollicis muscle in ulnar nerve palsy.

The adductor pollicis muscle has two heads:

1. Transverse Head – which originates from the anterior body of the third metacarpal.
2. Oblique Head – which originates from the base of the second and third metacarpals as well as the trapezoid and capitate bones.

The two heads of the adductor pollicis muscle then insert into the base of the proximal phalanx of the thumb and the ulnar sesamoid bone. The muscle is innervated by the deep branch of the Ulnar Nerve. The adductor pollicis muscle function is to adduct the thumb. It is important in pinch strength. When the ulnar nerve is injured, the adductor pollicis function is lost and thumb adduction will not occur.





THE UNIVERSITY OF TOLEDO
MEDICAL CENTER

Department of Orthopaedic Surgery
The University of Toledo
3000 Arlington Ave.
Toledo, Ohio 43614

Non-Profit
Organization
U.S. POSTAGE
PAID
Toledo, OH
Permit No. 161

Froment's Sign continued

The Froment's Sign is used to test the function of the adductor pollicis muscle. When pinching a piece of paper between the thumb and index finger against resistance, the thumb PI joint will flex if the adductor pollicis muscle is weak.

The flexion of the thumb occurs by the flexor pollicis longus which is innervated by the median nerve. The flexor pollicis longus, which is innervated by the median nerve, substitutes the function of the adductor pollicis which is innervated by the ulnar nerve.

THE UNIVERSITY OF TOLEDO MEDICAL CENTER
**ORTHOPAEDIC
MONTHLY**

Editors:

Dr. Nabil Ebraheim,
department chairman
and professor of orthopaedics,
and **Amanda Kaverman,**
assistant to the chairman.

Neither Dr. Ebraheim nor
Amanda Kaverman have any
relationships with industry to
disclose.

**Department of
Orthopaedic Surgery**
The University of Toledo
3000 Arlington Ave.
Toledo, Ohio 43614

For appointments, call
419.383.3761.