



THE UNIVERSITY OF TOLEDO MEDICAL CENTER

ORTHOPAEDIC MONTHLY

VOLUME 6, ISSUE 4 SEPTEMBER 2016

Little Leaguer's Shoulder

By: Nabil Ebraheim, MD

The "little leaguer's shoulder" is a stress fracture of the growth plate of the proximal humerus. It usually occurs due to a throwing motion and is considered to be a fracture of the physal growth plate (Salter-Harris Type I).

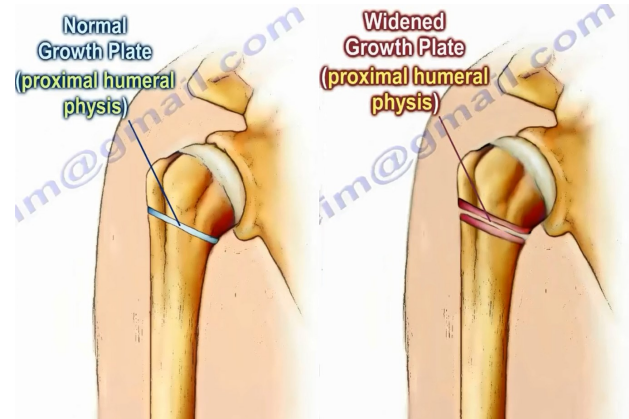
The overuse, repeated high loads of torque and rapidly growing child causes microtrauma to the physis. This injury is seen mostly in adolescence, pitchers and tennis players. This overuse injury is associated with pitching and is influenced by the quantity, intensity and age of the player.

Symptoms: Shoulder pain that worsens with throwing as well as tenderness over the physis of the proximal humerus. Rule out an injury to the sub-deltoid bursa. The pain will usually improve with rest.

X-rays will show a widened physis compared to the other side. There will be fragmentation and sclerosis of the lateral aspect of the proximal humerus in the physal area.

To prevent little leaguer's shoulder, avoid the overuse.

Treatment of little leaguer's shoulder:



- Cessation of throwing for about 2-3 months.
- Progressive throwing program.
- Rotator cuff strengthening once full painless range of motion is achieved.

Complications

- Premature growth arrest.
- Physal fracture.

Diagnosis and Management of Compartment Syndrome

Syndrome

By: Johnathan Cooper: Research Assistant to Dr. Ebraheim

Compartment syndrome (CS) is an urgent medical condition in which increased pressure within a closed fascial space compromises the circulation and reduces perfusion to tissues contained within the space. Compartment syndrome must be relieved within 6 hours to prevent tissue ischemia.

CS lasting for 8 hours or more may result in irreversible damage to muscles and nerves. Compartment syndrome can be either acute or chronic.

*** Sources for increased pressure include blood, edema

*** Fascia is thin sheaths of fibrous tissue enclosing muscles and organs.

Acute compartment syndrome may result from any of the following incidents: bone fracture, decreased compartment size, soft tissue injury, and vascular injury. Other more infrequent causes include gunshot wounds, arterial lines, temporary ischemia, prolonged limb compression, fluid infusion, and burns.

Continued on page 2



Compartment Syndrome continued

Chronic exertional compartment syndrome is exercise induced. It occurs when a compartment cannot accommodate the increase in muscle volume during exercise. It most often develops in the leg.

Risk Factors: Young age, male, tibia fracture, high-energy forearm fracture, high energy femoral fracture and bleeding diathesis/anticoagulants increase the risk of developing ACS.

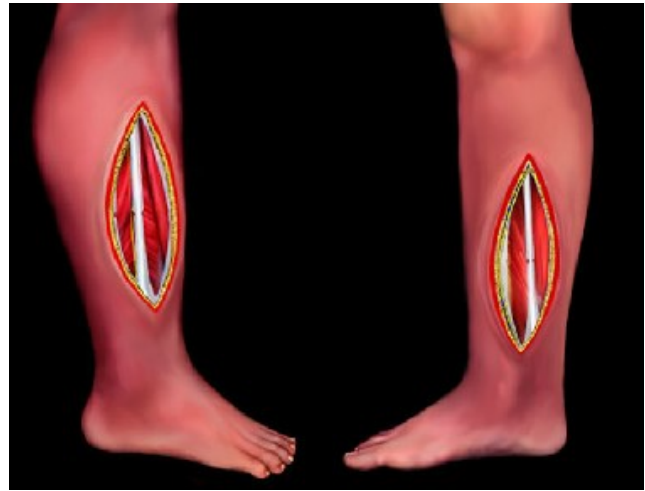
Diagnosis: Initial clinical signs for diagnosis of CS include pain out of proportion to primary injury or surgery, swollen and tense compartment and pain with passive stretch. Late clinical signs include paresthesia, paresis and pulselessness. Do not wait for late findings to establish a diagnosis.

Pressure monitoring can be used to establish a diagnosis of CS. An absolute pressure of 40 mmHg or within 30 mmHg of the diastolic blood pressure is required for diagnosis.

Differential Diagnosis: Neuroproxia and arterial occlusion both have similar findings to CS, and can be mistaken for CS during diagnosis. There are three simple techniques to tell the difference between each condition. First, if high intra-compartmental pressure is detected (>30 mmHg), the patient likely has compartment syndrome. Secondly, if the patient has no pain with passive stretch, but their pulses are intact, they likely have neuroproxia. Finally, if the patient lacks a pulse, but has pain with passive stretch and normal intra-compartmental pressure, they likely have arterial occlusion.

Treatment: Release of constrictive dressings should be performed when severe pain or neurological deficit is observed within 6 hours.

Once the diagnosis of CS is established, fasciotomy is indicated emergently. Decompression of all compartments with elevated pressure is mandatory (through multiple generous incisions if necessary).



****Fasciotomy is a surgical procedure in which the fascia is incised along the length of the compartment.*

Bedside fasciotomy is an acceptable form of treatment if it cannot be done in the OR.

Wound Management: As large open wounds are susceptible to infection, either wet-to-dry dressings or the VAC system is applied to the wound primarily after surgery. This step keeps the wound clean as the muscle shrinks back to an acceptable size for wound closure.

The second step occurs 48 to 72 hours after surgery. A second look is taken inside the wound to observe how the compartment is and whether the wound can be closed immediately or if it cannot. If the wound is ready to be closed, stitches or a skin graft can be used to close the wound.

If the wound is not ready to close, continuous traction techniques can be used to slowly close the wound over the course of a few days, sutures, wires and elastic loops are used to gradually close the wound. Tissue expanders such as derma close are used at the end of continuous traction to finish closing the wound.

Coracobrachialis, Brachialis and Brachioradialis

The coracobrachialis, brachialis and brachioradialis are confusing muscles to remember!

How do you sort these muscles out? What is the important anatomical feature for each of these three muscles? Start from proximal to distal!

The musculocutaneous nerve comes earlier than the radial nerve in the brachial plexus.

The musculocutaneous nerve supplies the coracobrachialis

and the brachialis muscle.

Musculo – it is the primary nerve supply of the muscles of the anterior compartment of the upper arm.

Cutaneous – it supplies sensation to the lateral half of the forearm.

The **coracobrachialis muscle** origin comes from the tip of the coracoid.

Continued on page 3

Coracobrachialis continued

You need to recognize that there are other muscles in the area of the coracoid. Next to these tendons is the pectoralis minor muscle.

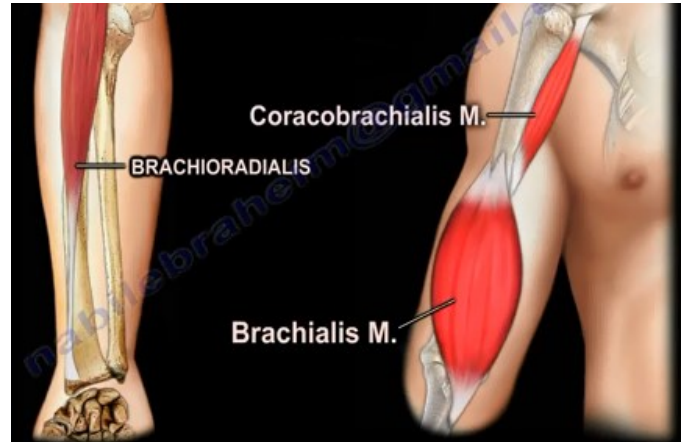
In the vicinity of these tendons are the coracoclavicular ligaments. The coracobrachialis inserts into the middle third of the medial border of the humeral diaphysis. The function of the coracobrachialis muscle is to flex and adduct the arm. The innervation of the coracobrachialis comes from the musculocutaneous nerve.

What is the important feature of the coracobrachialis muscle?

- Coracobrachialis muscle comes from the coracoid
- Musculocutaneous nerve is close to the coracobrachialis muscle.
- Musculocutaneous nerve pierces the coracobrachialis about 3-8 cm distal to the coracoid where it then gives a branch to the coracobrachialis muscle (some studies show that the nerve may be 1-5 cm from the coracoid).
- It runs between the biceps and brachialis muscles on the anterior compartment of the arm.
- You may not be able to measure the deficit except for decreased sensation on the area supplied by the lateral antebrachial cutaneous nerve.
- The lateral antebrachial cutaneous nerve could be injured during distal biceps repair.
- Be careful when retracting the conjoined tendon during anterior shoulder surgery.

The **brachialis muscle** originates from the lower half (distal) of the anterior aspect of the humerus. The brachialis muscle inserts into the coronoid process and tuberosity of the ulna.

The brachialis muscle is a major elbow flexor which flexes the forearm in all positions. The brachialis muscle is supplied by both the musculocutaneous and radial nerves. The important feature of this muscle is the fact that it has dual innervation.



Anterior approach to the humerus (splitting the brachialis) – curved incision is made from the tip of the coracoid process along the anterolateral aspect of the humerus. During the procedure, the brachialis is split in the middle after retraction of the biceps muscle.

The **brachioradialis** originates from the proximal 2/3 of the lateral supracondylar ridge of the humerus. It inserts into the lateral aspect of the styloid process of the radius and is innervated by the radial nerve. The brachioradialis is the first muscle to recover after injury to the radial nerve above it. Test the brachioradialis muscle with radial nerve palsy.

The radial nerve gives three branches before it splits: the brachioradialis, ECRL, and the ECRB.

The superficial sensory branch of the radial nerve runs distally in the forearm under the brachioradialis and lateral to the radial artery. When you expose the anterior shaft of the radius, the superficial branch of the radial nerve could be injured. **Wartenberg Syndrome** may occur when the superficial sensory radial nerve is compressed by the scissoring effect of the brachioradialis and ECRL tendon during forearm pronation.

Isolated Fibular Fractures

Fibular fractures are usually associated with a complex injury; however they can be an isolated fracture.

Complex injuries occurring with fracture of the fibula:

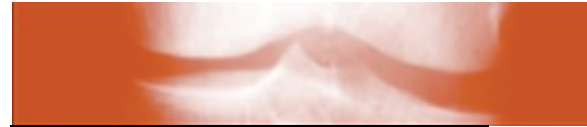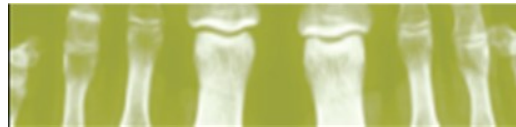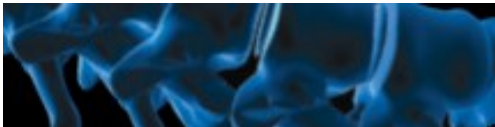- Fracture of the fibula and tibia.
- Ankle fracture – bimalleolar fracture, trimalleolar fracture.
- Fibular fracture with pilon fracture (fractures of the tibial plafond)
- Maisonneuve fracture – maisonneuve fracture involves fracture of the proximal fibula associated with an occult injury of the ankle

Continued on back page



THE UNIVERSITY OF TOLEDO
MEDICAL CENTER

Department of Orthopaedic Surgery
The University of Toledo
3000 Arlington Ave., MS 1094
Toledo, Ohio 43614



Isolated Fibular Fracture continued

The fibula carries about 15% of the axial load. The fibula is the site of muscle attachment for the peroneus muscles and the flexor hallucis longus muscle.

Maisonneuve fracture – check the patient who has a fibular fracture and no other fracture involving the tibia to rule out a possible maisonneuve fracture, especially if there is no history of direct trauma to the leg. A high index of suspicion is necessary to diagnose and treat this injury!

Look for signs of syndesmotic injury:

- Unexplained increase in medial clear space
- Tibiofibular clear space is widened (should be less than 5 mm)

The x-ray will show the fracture to be rotational or oblique. Maisonneuve fractures require surgery to fix the syndesmosis.

Treatment:

- Reduction
- Fixation – syndesmotic screws

It is important to determine if the injury is a maisonneuve fracture or an isolated fibular fracture. An isolated fibular fracture will not need surgery.

THE UNIVERSITY OF TOLEDO MEDICAL CENTER
**ORTHOPAEDIC
MONTHLY**

Editors:

Dr. Nabil Ebraheim, Professor and Department Chairman of Orthopaedic Surgery; **Amanda Critton**; **Julie Anderson** and **Ellen Finch**

Guest Author: Johnathan Cooper - Student - Kenyon College

Dr. Ebraheim, Amanda Critton, Julie Anderson; Ellen Finch; and Johnathan Cooper do not have any relationships with industry to disclose.

Department of Orthopaedic Surgery
The University of Toledo 3000 Arlington Ave., MS 1094 Toledo, Ohio 43614

For appointments, call 419.383.3761