

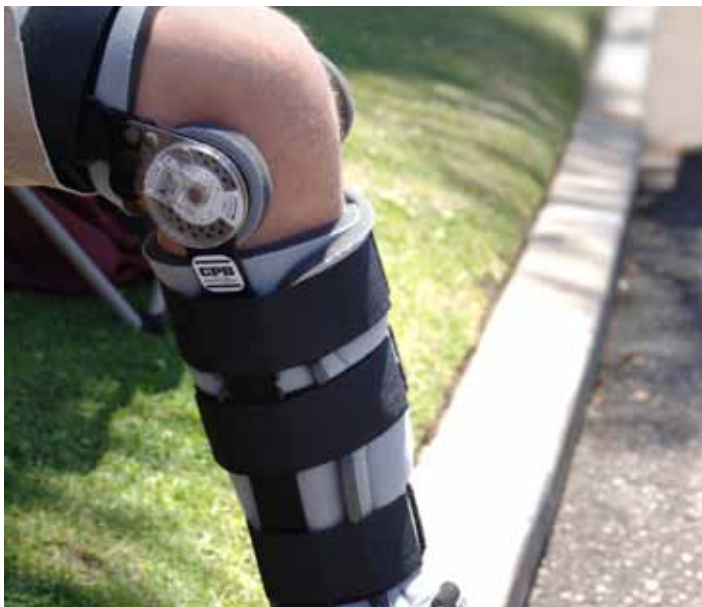

THE UNIVERSITY OF TOLEDO MEDICAL CENTER

# ORTHOPAEDIC MONTHLY

VOLUME 3, ISSUE 4 APRIL 2009

## Department of Orthopaedic Surgery Awarded \$1.2 Million Grant to Study ACL Injuries



*ACL injury rehabilitation*

UTMC's Department of Orthopaedic Surgery, in conjunction with the University of Cincinnati, recently received a grant for over \$2 million (approximately \$1.2 million will come to UT) to study female anterior cruciate ligament (ACL) injuries.

Dr. Vijay Goel, a faculty member in the departments of Orthopaedic Surgery and Bioengineering, was instrumental in attaining the grant. Along with Dr. Nabil Ebraheim, Chair of Orthopaedic Surgery, Dr. Goel is Co-Director of the Engineering Center for Orthopaedic Research Excellence. Carmen Quatman, an MD/PhD Pre-Doctoral Fellow at the University, was pivotal in attaining the grant. Quatman's interest in ACL injuries stems from suffering an ACL injury which ultimately resulted in six major knee surgeries. According to Quatman, she witnessed first-hand the devastating, sometimes career-ending effects of ACL injuries for 12 of her teammates during a four-year period.

The ACL is one of the most commonly injured ligaments of the knee, with female athletes sustaining these injuries at a rate two-to-eight fold greater than male athletes. An ACL injury can be devastating and can significantly increase the athlete's risk for osteoarthritis in the long term. While many advances have been

made in surgical and rehabilitation treatments for patients with ACL injuries, outcome studies show these patients are at high risk for developing knee osteoarthritis 10 to 15 years after the ACL injury, regardless of the treatment.

The mechanism of non-contact ACL injury is not well understood. In order to design successful ACL injury prevention programs and address the high rates of ACL injuries in the female athlete population, a better understanding of the non-contact ACL injury mechanism needed to be established. Both biomechanical data and video analyses indicate that increased abduction loads in the lower extremities may be associated with increased ACL strain and risk of injury. However, the medial collateral ligament (MCL) is considered to be the primary restraint against abduction stress in the knee joint.

Clinicians and biomechanists are unable to explain why ACL ruptures, without MCL injuries, are significantly more common than combined ACL/MCL injuries. Dr. Goel and the Department of Orthopaedic Surgery hypothesized that coupled abduction and anterior knee joint loads near full knee extension will lead to disproportional increases in ACL strain relative to MCL strain and leads to ACL failure loads without concomitant MCL failure loads in female athletes. They proposed to use a unique blend of the current methods used to investigate ACL injury mechanisms in order to gain an in-depth understanding of knee ligament biomechanics during high knee loading conditions. Specifically, the aim is to determine the mechanical responses of the ACL and the MCL to loads using cadaveric testing, computer mathematical modeling and three-dimensional motion analysis.

Identifying ACL injury mechanisms may help develop ACL injury prevention programs that would allow many athletes to receive the health benefits of sports participation and avoid the long-term sequelae of disability associated with knee osteoarthritis.

In addition to Dr. Goel's research work, the Department of Orthopaedic Surgery continues to make strides in the field of orthopaedic research. Dr. Champa Jayasuriya, assistant professor of Orthopaedic Surgery, continues to work on bone tissue engineering, while Dr. Beata Lecka-Czernik, professor of Orthopaedic Surgery, continues to work on the affects of diabetes and medications on bone. The department is actively developing its own PhD program in orthopaedic trauma and diseases.

## Common Achilles Tendon Problems

The Achilles tendon is a fibrous tendon of the posterior leg attaching the calf to the calcaneus (heel bone). It is the strongest and thickest tendon in the body. Contraction of the calf muscle pulls the Achilles tendon, pushing the foot downward. This contraction is essential for movement such as walking, running, jumping and standing on the toes. While the Achilles tendon is the strongest tendon in the body, it is susceptible to injury due to forces it is subjected to and limited blood supply.

Common Achilles tendon problems include Achilles tendonitis, Achilles tendon rupture and Tendocalcaneal bursitis. In addition, medications such as Cipro and Levaquin have also been linked to Achilles tendon injury.

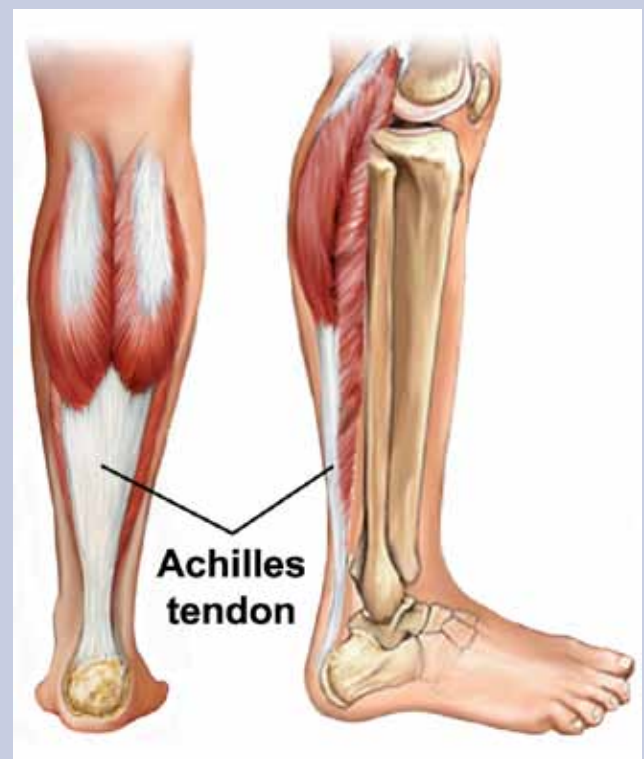
Achilles tendonitis refers to an inflammation of the Achilles tendon. While this injury is manageable, it can progress over time and cause degeneration of the tendon; this condition is known as Achilles tendonosis. Patients with Achilles tendonitis will usually present with localized pain over the tendon, pain following exercise, stiffness, swelling and redness over the skin. Causes for Achilles tendonitis include overuse, trauma, increasing activity level too rapidly, or adding different modes of training such as hill climbing. Diagnosis of Achilles tendonitis can be achieved through a physical examination. However, physicians may order x-rays or an MRI to rule out other possible injuries. Achilles tendonitis can usually be treated conservatively with a combination of rest, ice, physical therapy, anti-inflammatory medications, shoe inserts, injections and a change in training modalities. If conservative treatment fails, however, the inflamed tissue around the tendon may need to be removed.

If you overexert your Achilles tendon it may tear (rupture) partially or completely. Achilles tendon ruptures are often missed during diagnosis because they can be misdiagnosed as ankle sprains, peroneal injuries, tibialis tendon injuries, and calf and muscle strains. Partial tears may be particularly difficult to diagnose, as a patient may be able to walk, flex the plantar muscle against resistance and lack pain. Patients with an Achilles tendon rupture will present with pain, an inability to bend their foot downward or walk, and an inability to move the toes upwards. To diagnose an Achilles tendon rupture, physicians will typically use three tests during physical examination: palpation; the Thompson test; and the Matles test. To correctly diagnose a ruptured Achilles tendon, a physician should palpate the tendon along the entire length. To conduct a Thompson test, the patient is asked to lie prone on the examination table with the foot extended beyond the end of the table. The physician will then squeeze the calf. A non-injured response to this maneuver is a slight plantar flexion (movement which increases the angle between the foot and the leg). Lack of movement can indicate a rupture. To perform a Matles test, the patient is asked to actively flex the knee through 90 degrees while in the prone position. An intact tendon should display the foot with slight plantar flexion. If the foot falls into the neutral position or dorsiflexion, a rupture is possible. To confirm physical examination findings, MRI imaging is often utilized. For a tendon

rupture, the most common treatment is surgical intervention. Here, the physician will make an incision in the back of the leg and stitch the tendon together. Following surgery, the tendon will be immobilized for six to eight weeks to allow for healing. While surgical intervention is most common, the tear can be managed conservatively. Treatment would include immobilization with a cast or a boot to allow the tendon to reconnect. However, a re-rupture is more likely and there is a slower recovery time.

Another Achilles tendon problem is tendocalcaneal bursitis. The bursa is a fluid-filled sac limiting friction and allowing the body's parts to move and rub each other without catching. Tendocalcaneal bursitis refers to an inflammation in the bursa behind the heel bone which limits the friction where the tendon runs down the calf and behind the heel. This type of bursitis usually begins with irritation and pain on the calcaneus (heel bone). Patients with tendocalcaneal bursitis will present with visible redness or swelling.

Achilles tendon ruptures have been linked to medication use. Fluoroquinolone antibiotics, which are often used to treat urinary tract infections and respiratory infections, have been associated with Achilles tendon rupture. Cipro and Levaquin, which are antibacterial agents with bactericidal activity, have been linked specifically to Achilles tendon ruptures. While the cause is unclear, patients should seek alternative medication if they experience Achilles tendon pain while taking these antibiotics.

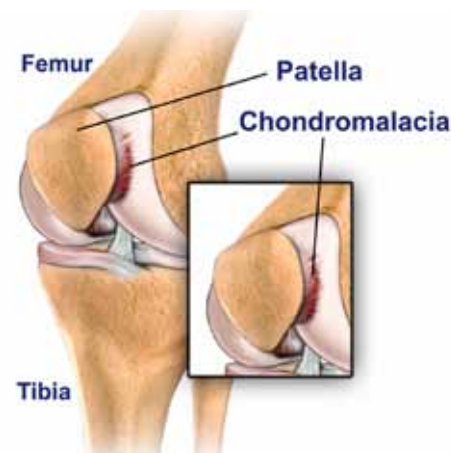

*Depiction of an Achilles tendon*

# Patellar Injuries and Conditions

The knee joint is comprised of three bones: the patella, the femur, and the tibia. Also known as the kneecap, the patella is the thick, triangular, moveable bone that forms the anterior point of the knee responsible for covering and protecting the knee joint. The patella is wrapped inside a tendon and connects the quadriceps muscle to the tibia through the patellar tendon. The bones of the knee joint are covered with cartilage where their surfaces come into contact.

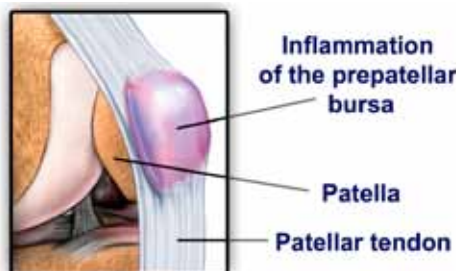
Knee pain is a relatively common problem that can be attributed to conditions and injuries including: chondromalacia, pre-patellar bursitis, patellar subluxation/dislocation and fractures of the patella.



Depiction of chondromalacia

Chondromalacia, also known as runner's knee, is an irritation of the articular cartilage on the undersurface of the kneecap. Patients with chondromalacia typically have abnormal lateral patella tracking which allows the undersurface of the patella to rub against the femur. In other words, the pain and degeneration is due to poor alignment of the

kneecap. This constant rubbing can cause pain and inflammation. Patients presenting with chondromalacia will usually complain of knee pain of the inner knee area. Often, symptoms are exacerbated with activity or prolonged sitting. Chondromalacia can often be treated with a combination of rest and physical therapy. However, there are instances where surgery is needed to correct the misaligned knee joint.

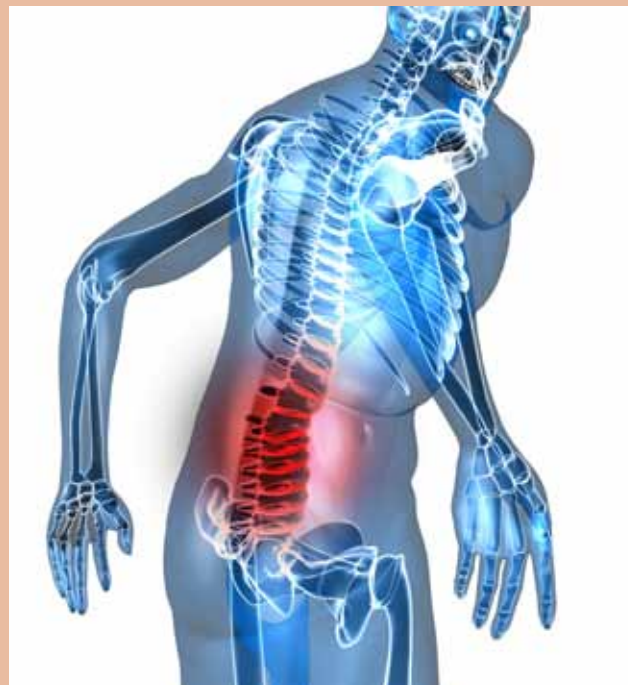

Bursitis of the patella

Another common patella condition is bursitis. This refers to swelling and inflammation of the knee's bursa located over the front of the knee. The bursa is a fluid-filled sack holding lubricating

fluid that allows movement between different tissues without irritation or catching. Patients with knee bursitis would present with decreased range of motion, painful movement and swelling of the knee joint. Bursitis can typically be treated conservatively with rest

# Detecting Patients that May Exaggerate or Overreact



Depiction of lower back pain

While most patient complaints are genuine and sincere, there are times when patients fabricate or exaggerate symptoms of physical disorders. This type of patient is known as the malingering patient, a medical and psychological term that refers to an individual fabricating or exaggerating the symptoms of mental or physical disorders for a variety of reasons.

For patients with low back pain, orthopaedic surgeons utilize the Waddell sign. This refers to a group of physical signs that may indicate a psychological or non-organic component of chronic low back pain. The Waddell sign uses five tests to determine non-organic components of low back pain:

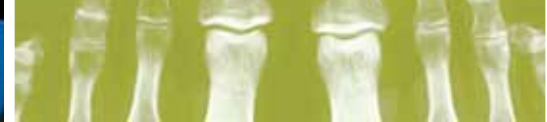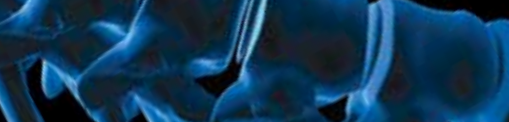- 1) simulation test (back pain with axial compression or with rotation of the shoulder in the same plain with the pelvis);
- 2) flip/distraction test (no back pain with sitting SLR-sitting hip 90 degrees and knee extended);
- 3) overreacting patient;
- 4) back pain with superficial palpation or pinching of the back;
- and 5) decrease of sensation doesn't correlate with motor and radiologic findings.

It is important to understand, however, that there is no objective examination technique to prove a malingering patient. Red flags for a malingering patient are inconsistency between symptoms and the doctor's examination and a non-complaint patient. If you are in doubt about the condition of the patient, always assume they are not malingering until proof indicates otherwise.

Evidence of certain gain or reward from illness should increase suspicion of malingering; however, the physician shouldn't be judgmental and should exclude all possible pathologic causes of back pain.

*continued on p. 4*





# Patella

*continued on p. 4*

and ice to decrease the swelling. However, a physician may choose to aspirate (drain) the bursa with a needle if swelling is significant or if the bursa is infected.

A third condition that affects the patella is subluxation or dislocation. Patellar subluxation refers to a patella that does not track evenly within the groove of the femur. Improper tracking of the patella may lead to dislocation, (where the kneecap fully dislocates out of the groove). The patella is usually dislocated laterally. X-rays should be carefully evaluated for the presence of osteochondral fragments displaced within the knee joint. Sunrise view will demonstrate lateral dislocation of the patella. Patients should be examined for signs of patellar instability in the unaffected knee. Treatment for non-displaced osteochondral fractures is closed reduction and knee immobilization for two weeks. Displaced osteochondral fracture treatment includes removal of osteochondral fragments and repair of the disrupted medial tissues.

Fractures of the patella are another problem associated with the kneecap. They result in disruption of the extensor mechanism of the knee joint. Patients with fractures of the patella will be unable to extend the knee. A straight leg raise test is often utilized to test

the function of the quadriceps muscle and its attachment to the tibia. To perform the test, the patients lie flat on a bed with their leg straight, raise their foot and hold it in the air. The straight leg raise tests the function of the quadriceps muscle and its attachment to the tibia. A disruption of the quadriceps tendon, patella, or patellar tendon can lead to an inability to perform a straight leg raise. Treatment for displaced fractures includes open reduction and internal fixation. For highly comminuted fractures, a patellectomy (surgical removal of the patella) is needed. For non-displaced fractures, a cast is utilized.

THE UNIVERSITY OF TOLEDO MEDICAL CENTER

## ORTHOPAEDIC MONTHLY

Editors: Dr. Nabil Ebraheim, department chairman and professor of orthopaedics, and Dave Kubacki, assistant to the chairman.

Department of Orthopaedic Surgery  
3000 Arlington Ave  
Toledo, Ohio 43614  
For appointments, call 419.383.3761.

Neither Dr. Ebraheim nor Dave Kubacki have any relationships with industry to disclose.

UTMC 376 509 25C

Non-Profit  
Organization  
U.S. POSTAGE  
PAID  
Toledo, OH  
Permit No. 161

Department of Orthopaedic Surgery  
The University of Toledo  
3000 Arlington Ave  
Toledo, Ohio 43614

THE UNIVERSITY OF TOLEDO  
MEDICAL CENTER

