



THE UNIVERSITY OF TOLEDO MEDICAL CENTER

ORTHOPAEDIC MONTHLY

VOLUME 2, ISSUE 7 AUGUST 2008

Orthopaedic Center Growing *Residency Review Committee Approves Orthopaedic Center's Residency Program Request for an Additional Resident per Year*

Just three months after the Accreditation Council for Graduate Medical Education's (ACGME) Residency Review Committee commended the UT Orthopaedic Center's residency program for its demonstrated substantial compliance with the ACGME's requirements for Graduate Medical Education with five years continued accreditation, it was awarded an increase in resident complement. The increase will provide an extra resident per level of training, increasing the total number of residents in the orthopaedic program at the UT Medical Center from 15 to 20 (from three to four each level).

The increase in resident complement accompanies the Orthopaedic Center's recent efforts to expand clinically, educationally and in research. The decision was reached following the Residency Review Committee's meeting on June 13. The residents

have a 100-percent passing board rate and always obtain a near-perfect score on the American Academy of Orthopaedic Surgeons (AAOS) orthopaedic in-training examination.

Clinically, the Orthopaedic Center has experienced growth by providing a high level of access, service and convenience to patients who now can be seen by a world-class orthopaedic surgeon within 24 hours of calling the Center or immediately if it's an emergency. With the acquisition of an in-house MRI, patients have virtually no reason to leave the Orthopaedic Center during appointments. The Center houses all services in one convenient location including: valet parking; a coffee/desert bar; on-site registration; digital, dexta and MRI imaging; outpatient lab work; urgent care; outpatient procedures; soft good and cast rooms; an educational conference

Continued on page 2.

John M. Howard Endowed Professorship of Surgery Fund Established



Dr. John M. Howard

In honor of his distinguished career as a surgeon, both in the United States and internationally, the UT Department of Surgery and John M. Howard's family and friends established an endowed professorship in his name that will focus on research and education in the areas selected by Dr. Howard – pancreatic cancer and the surgical treatment of pancreatic cancer. The faculty members in the Orthopaedic Center made a significant contribution to the establishment of the fund, which currently totals nearly \$500,000.

Since joining the Department of Surgery in 1975, Dr. Howard has educated, trained and mentored hundreds of medical students and junior faculty. One year out of residency, Dr. Howard directed the U.S. Army's Surgical Research Team in Korea during the Korean War. His team introduced the successful repair of arterial injuries, opening the field of peripheral arterial surgery. For his work he was awarded the

Legion of Merit by order of President Dwight D. Eisenhower.

For a decade, Dr. Howard chaired the committees on Shock and the Emergency Medical Services of the National Research Council – the organization created by Abraham Lincoln to advise the government on matters of science. In addition, he was founder and one-time president of the American Trauma Society from which he received its Award of Achievement.

Dr. Howard is a fellow of the American College of Surgeons and the American Surgical Association, holding honorary fellowships in the Royal College of Surgeons of Edinburgh, the College of Surgeons in Brazil and the Japanese Association of Hepato-Biliary Pancreatic Surgery. Dr. Howard's bibliography includes more than 400 surgical papers. He is also the author or editor of 11 books.

The Orthopaedic Center looks forward to honoring Dr. Howard as a mentor, teacher, and distinguished colleague and researcher. We are proud that he is part of the University and hope that others will join in and support this professorship. If you wish to make a contribution to the fund, please contact Howard Newman at 419.383.6849.



What is Whiplash?

For those who have been in a rear-end auto collision, the word whiplash may mean a lot. It's a common injury that has become a household name. Each year there are about 2.5 million rear-end auto collisions. So what exactly is whiplash?

Whiplash is a non-medical term that implies injury to the soft tissues of the neck, specifically ligaments, tendons and muscles. It is characterized by a collection of symptoms that occur following damage to the neck, usually because of sudden extension or flexion from extreme motions pushing neck muscles and ligaments beyond their normal range of motion. Injuries can range from minor tears of the sternocleidomastoid muscle to partial avulsions of the longus coli and retropharyngeal hematomas. Other common findings include:

- Intervertebral disc failures;
- Tears of one or both of the anterior longitudinal ligament;
- Soft tissue injury of the facet joints;
- Dorsal root ganglia contusions; and
- Damage to the vertebral arteries.

Whiplash is most commonly caused or associated with motor vehicle accidents. However, contact sport injuries, blows to the head, repetitive stress injuries, and chronic strain are also common whiplash causes. Child abuse, particularly the shaking of a child, can also result in this injury as well as in more serious injuries to the child's brain or spinal cord.

Whiplash may be difficult to diagnose as it may occur immediately or minutes to hours after the initial injury. Patients may experience:

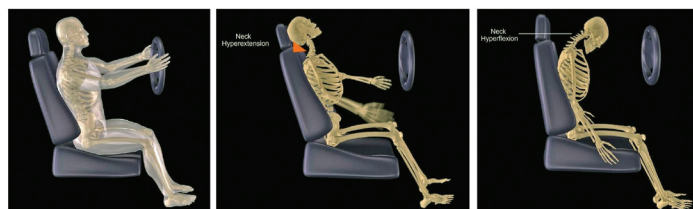- Diffuse neck pain, tenderness and stiffness
- Muscle spasms as a result of injuries to the muscles or ligaments
- Headache, dizziness, nausea and blurred vision (symptoms of a concussion)
- Difficulty swallowing and chewing and hoarseness (could include injury to the esophagus and larynx)

- Abnormal sensations such as burning or prickling (this is called paresthesias)
- Shoulder and/or arm pain
- Back pain

Examination of the patient begins with a detailed patient history which should include:

- Mechanism and velocity of the injury;
- Delay between the injury and onset of symptoms;
- Additional related symptoms; and
- Review of previous neck injury

Radiographs or other imaging may also be utilized to determine if a fracture exists and to assess the condition of the cervical spine's soft tissue. The physical examination should



Rendering of the hyperextension and hyperflexion forces the neck sustains during a motor vehicle accident.

include palpation for areas of tenderness, cervical spinous processes, cervical paraspinal muscles, cervical nerve roots, and anterior cervical soft tissues. Lastly, the examiner should provide a neurologic examination to assess cranial nerves, cervical nerve-root, upper extremity function and reflex evaluation of the upper extremity.

To manage these injuries, doctors will usually immobilize the neck with a soft cervical collar which may need to be worn for two to three weeks. Other ways to manage whiplash include ice therapy, pain medications, muscle relaxants and possible surgical intervention.

Orthopaedic Center Growing

Continued from page 1.

center; 28 exam rooms equipped with state-of-the-art computer systems; and financial counseling. The Center understands the burden of rising gas prices so it offers patients the convenience of having consultations with other specialists.

The Orthopaedic Center's research efforts have been enhanced with a \$4.5 million grant from the state to support the development of a spinal cluster. The goals of the spinal cluster are to:

- Catalyze externally funded, cutting-edge basic and applied research in spinal diseases and devices;
- Generate new Ohio-based intellectual property and spin-off companies, to supplement Ohio Research Scholar Program funds through research dollars generated by scientists in the cluster, and;
- Train engineers, medical students, residents and fellows in moving new technologies from bench to bedside.

Dr. Vijay Goel, UT Endowed Chair and McMaster-Gardner Professor of Orthopaedic Bioengineering and co-director of the Engineering Center for Orthopaedic Research Excellence (E-CORE), was instrumental in obtaining the grant. The department also has two other research PhDs, Dr. Beata Lecka-Czernik and Dr. A. Champa Jayasuriya. In the next few months, doctors from all over the world including Egypt, India, Japan and China will be visiting the Orthopaedic Center.

The Orthopaedic Center would like to thank the University's administration for its support during the accreditation process. Special thanks go to Drs. Jeffrey P. Gold, provost and executive vice president for Health Affairs and dean of the College of Medicine, and Mary Smith, professor of pathology, and the staff of the GME office for their help and preparation for the accreditation visit and resident complement evaluation; your input has been invaluable.

Orthopaedic Emergencies

According to the American Academy of Orthopaedic Surgeons, orthopaedic complaints are the most common reason to seek medical care. In 2003 there were almost 56 million physician visits for musculoskeletal injuries accounting for 56 percent of all visits for injury. Because physician visits for orthopaedic injuries are so common, it's essential to know what constitutes an orthopaedic emergency.

An orthopaedic emergency is a condition or injury that requires urgent attention. Many orthopaedic emergencies stem from injuries surrounding the limbs or spinal cord. Any delay in seeking medical attention may negatively affect the short-term or long-term functioning of the spinal cord or limbs. Early detection and treatment enhances the chance of limb survival and normal spinal cord functioning. Common orthopaedic emergencies include open fractures, fractures with vascular injury, pelvic fractures, hip dislocations, knee dislocations, compartment syndrome, and spinal cord and cauda equina injuries.

An open fracture includes damage to the skin and soft tissue, leading to contamination of the fracture site from the outside environment. The major concern is infection associated with the size of the wound – which may cause delayed or a complete lack of healing – and the amount of muscle and soft tissue damage. Patients with open fractures must come to the hospital as soon as possible to have the wound washed and examined to determine the extent of damage to the soft tissue and bone.

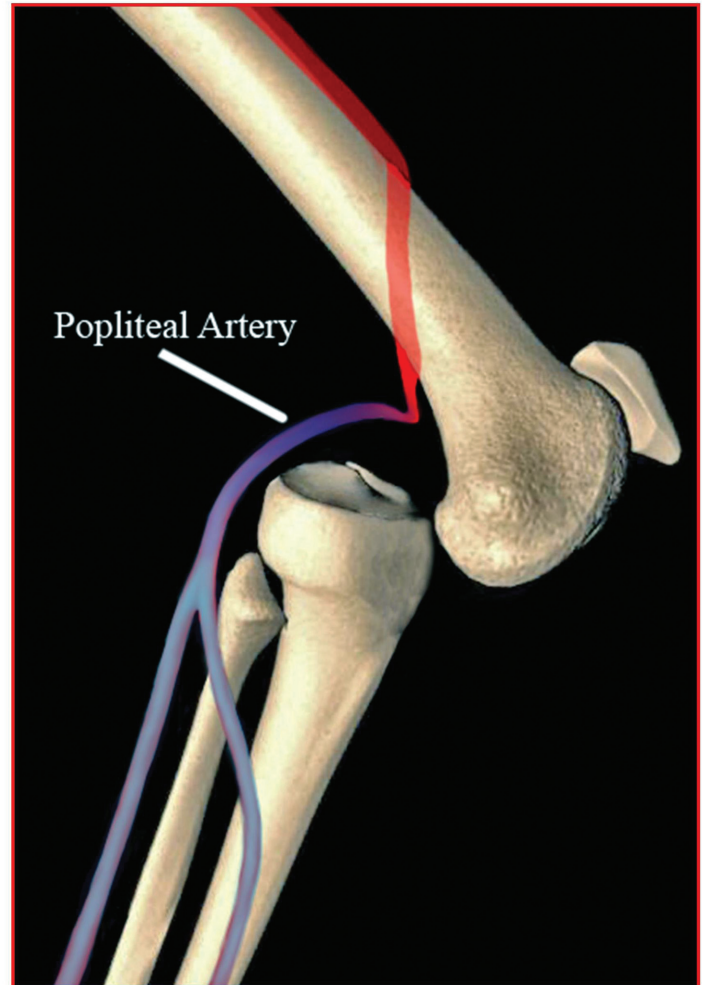
During irrigation and debridement, a copious amount of normal saline is used to remove as much of the contamination and dead tissue as possible. The procedure may improve blood supply to the injured area, helping decrease the chance of infection while promoting healing.

Another major orthopaedic emergency is a fracture associated with a vascular injury. When a fracture includes a major arterial injury, there is a concern for the limb's survival. The most common fractures associated with vascular injuries are fractures around the knee and elbow, although they can occur elsewhere in the extremities. If the blood supply is not restored within six to eight hours of the injury, gangrene of the limb will occur.

These fractures need urgent stabilization and exploration to assess the damaged artery.

The third type of orthopaedic emergency is a pelvic fracture, which occurs as a result of high-energy trauma. Most pelvic fractures are associated with severe bleeding in the pelvis. If they are not treated in a timely manner, they may result in hypovolemic shock and death. Urgent treatment with blood transfusion to replace lost blood is essential. In addition, the pelvis needs to be stabilized with external fixation.

Hip dislocations are another type of orthopaedic emergency. A hip dislocation is when the head of the femur slips out of its socket in the pelvis. This type of dislocation results in damage to the blood supply to the femoral head and, if not reduced immediately, may result in permanent damage or loss of blood supply to the femoral head, resulting in avascular necrosis. Avascular necrosis results in degenerative arthritis of the hip,



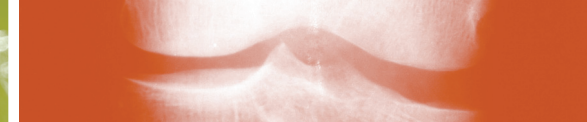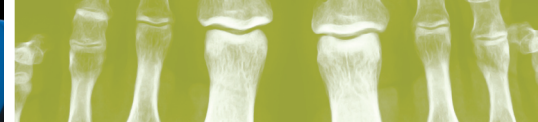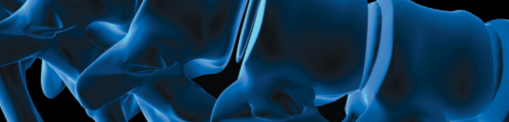
Rendering of a knee dislocation.

pain, and loss of motion at the hip. Hip dislocations should be recognized and treated as early as possible.

Another dislocation that is considered an orthopaedic emergency is a knee dislocation, which results in damage to the popliteal artery. It is necessary to reduce the dislocation, aggressively check the circulation, explore the artery and repair it if necessary.

Compartment syndrome is an orthopaedic emergency that requires immediate attention. Patients with compartment syndrome have increased pressure within closed fascial compartments of the limb, resulting in decreased blood flow. This leads to muscle and nerve ischemia. Compartment syndrome is most common following fractures of the tibia and forearm. A patient's limb presenting with compartment syndrome will appear very swollen and the skin will be very shiny. In addition, patients will experience pain on passive movement of the toes or fingers. Late findings include numbness, paraesthesias, paralysis, and loss of pulse. If not treated immediately, compartment syndrome may lead to permanent muscle contracture and impairment of nerve function. Compartment syndrome should

Continued on page 4.



Orthopaedic Emergencies

Continued from page 3.

be treated immediately with stabilization of the fracture and opening up the tight fascial compartments by performing a fasciotomy.

Spinal cord and cauda equina injuries are also common orthopaedic emergencies. Fractures or dislocations of the vertebral column may result in compression of the spinal cord. Depending on the level of spinal cord injury, the patient may have paralysis of his/her four upper and lower limbs (quadriplegia) or the lower part of the body below the waist (paraplegia). Injury to the cauda equina results in loss of bowel, bladder and sexual functioning. Compression of the cervical spinal cord may result in respiratory compromise and death. Displaced fractures and dislocations should be reduced and stabilized as early as possible to minimize injury or permanent damage to the spinal cord. Studies have shown that when Methylprednisolone is administered within eight hours, outcomes are improved.

Clearly, orthopaedic emergencies are serious matters. Patients need to know what constitutes an orthopaedic emergency. In addition, they need to see a doctor immediately if they suspect they have sustained one of these serious injuries.

August 2008

Z A I O Z D Z J Q A S O F U I
 L O E D Q S P H K T Q K I R U
 H P P N P M E K Q N Z C Y L N
 L H Y P E R E X T E N S I O N
 I P E L V I C Q B X U V E S B
 G L J E C D T T Y B Q U D J M
 A P L A E T I L P O P T M X C
 M G U A S H O J W K K Z V Z U
 E L P N O I X E L F R E P Y H
 N V Y T N E M T R A P M O C F
 T Y O R T H O P A E D I C E K
 L F D J Y A M O T A M E H E E
 B T I M F Y Q V A S C U L A R
 D I S L O C A T I O N G Y B S
 E E J Q D G W H I P L A S H Y

WHIPLASH
 HYPEREXTENSION
 HYPERFLEXION
 ORTHOPAEDIC
 HEMATOMA
 LIGAMENT
 VASCULAR
 PELVIC
 COMPARTMENT
 DISLOCATION
 POPLITEAL

THE UNIVERSITY OF TOLEDO MEDICAL CENTER

ORTHOPAEDIC MONTHLY

Editors: Dr. Nabil Ebraheim, department chairman and professor of orthopaedics, and Dave Kubacki, assistant to the chairman.

Neither Dr. Ebraheim nor Dave Kubacki have any relationships with industry to disclose.

Department of Orthopaedic Surgery
3000 Arlington Ave
Toledo, Ohio 43614
For appointments, call 419.383.3761.

UTMC 53 608 25C

Non-Profit
 Organization
 U.S. POSTAGE
 PAID
 Toledo, OH
 Permit No. 951

Department of Orthopaedic Surgery
 The University of Toledo
 3000 Arlington Ave
 Toledo, Ohio 43614

