



THE UNIVERSITY OF TOLEDO MEDICAL CENTER

ORTHOPAEDIC MONTHLY

VOLUME 4, ISSUE 7 SEPTEMBER 2010

The Dilemma of Treating Injured Cartilage

Editorial by Dr. Nabil Ebraheim, chair and professor of orthopaedics

You can find cartilage in the joints of the body. It is responsible for providing the cushion between bones. Unlike other connective tissue, cartilage does not have blood vessels.

The best type of cartilage is known as hyaline cartilage. It is a smooth, crystal-clear type of cartilage that contains type II collagen, proteoglycans and microscopic structures that change with aging.

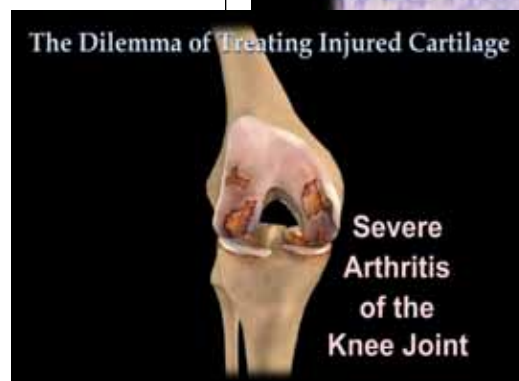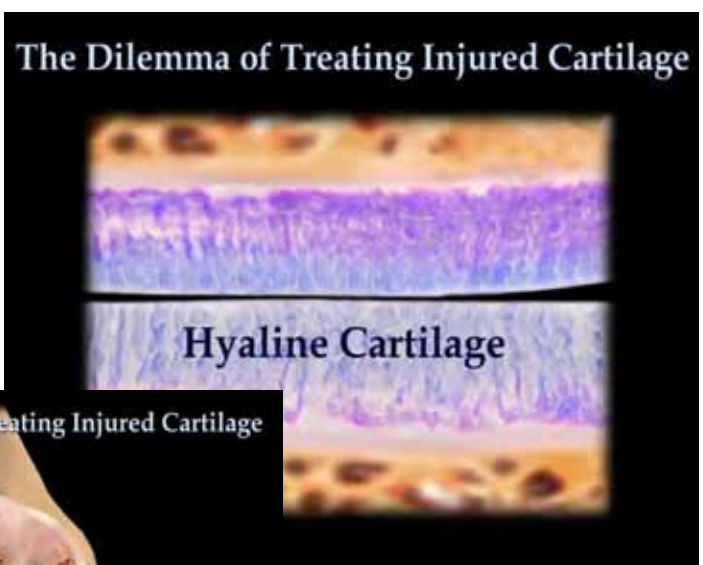When a bone is injured, it heals by bone and unites. When a muscle is injured, it heals with a scar. Moreover, if the patient undergoes therapy, the muscles increase in size and power, learning to compensate. However, when cartilage is injured, it does not get repaired with the same type of cartilage. Instead, it repairs itself with inferior cartilage known as fibro-cartilage. This type of cartilage fissures, and it crumbles under pressure; it is not strong and smooth like hyaline cartilage.

Cartilage cells are supposed to live forever and cannot be reproduced. Imagine that you have a car with a flat tire. An easy solution is to change the tire. What if you didn't have a spare tire? You'd have a car riding on its rims. The same is true of cartilage, as there is no adequate replacement. Therefore, most of the research in this area is intriguing because of the interest in making new cartilage. Physicians are trying to reduce pain and improve the function of the patient.

The knee is one of the most commonly affected joints with injured cartilage. There are several treatments, including therapy, medications, injections and topical modalities. However, these methods are not without drawbacks, complications or temporary effects. Some medications can cause cardiovascular or gastrointestinal problems. Some injections can cause cartilage damage or may help only temporarily.

When arthritis is severe, the treatment path is simple: A total knee replacement is needed. It's similar to the roof of a house. If a roof collapses, you need to replace it. If the cartilage damage is severe and you have constant, bone-on-bone interaction, you need a knee replacement.

There have been significant advances in total knee replacements, such as the use of gender knee replacements and patient-specific knees. Gender knee replacements are designed to fit the shape and size of each gender's



anatomy. They have a thinner profile, allow for more natural movement of the kneecap and have a shape specifically contoured for women. With patient-specific knees, pre-operative MRI or CT imaging of a patient's true knee anatomy and surgical planning using advanced software are created to specifically design the patient's knee replacement. Therefore, surgeons have the ability to not only customize the patient's surgery experience, but also to provide an implant uniquely matched to the patient's lifestyle. It's almost like going to a tailor and being custom-fitted for a suit.

While knee replacements are generally successful surgeries, there are still possible complications, including blood clots, infection, loosening of the implant and failure of the implant. Routinely, the patient will

have pre-operative clearance of their medical condition. Patients are also pre-operative and prophylactic antibiotics. In addition to antibiotics, blood thinner and physical therapy are given after surgery. Despite this treatment, complications may happen even in the best care.

When arthritis is mild, many treatments can work. Even drinking a cup of green tea or doing yoga can be helpful. If you think about the roof of a house again where you have a small leak, there are many easy fixes that will work, such as patching it.

The problem with injured cartilage is when it is moderate. Here, the arthritis is not severe enough for a total knee replacement, but not minimal enough for easy fixes. Moreover, the patient could be young. Physicians in this situation attempt to delay a total knee replacement, like patching the roof of a house. They may use injections such as hyaluronic acid or cortisone or try drilling and debridement to allow blood flow to

the affected area. Sometimes, all of these methods are used, and it does not work. Using our roof analogy, water is still leaking.

Physicians now focus on the origin of the problem and try to figure out if new hyaline cartilage can be grown. They try to use mesenchymal stem cells or platelets that can attract stem cells. They are interested in seeing if the body can use these primitive mesenchymal stem cells that hide in the bones. Physicians try to find them, aspirate them and inject them or grow them and inject them.

For now, each doctor uses methods with which he/she is comfortable. Unfortunately, it is not easy to figure out which method is best for each patient. Experiments and trials are needed to evaluate the efficacy of each method. What may work for you may not work for your neighbor.

For more information, please visit our YouTube video titled "The Dilemma of Injured Cartilage." ■

Click in the Hip

There are a variety of reasons patients present with a clicking or snapping sensation in the hip. It is essential for physicians to understand each cause to provide an effective course of treatment. A click in the hip can be the result of the following: a labral tear of the hip, tensor fascia lata, iliopsoas bursitis, iliopsoas tendon snap and arthritis of the hip.

A labral tear of the hip is a common cause for clicking sensations in the hip joint. The labrum refers to the ring of cartilage surrounding the socket of ball-and-socket joints. Also found in the shoulder, the labrum of the hip is essential in providing stability to the joint. Labral tears can be the result of degenerative (repetitive motions, osteoarthritis) or traumatic (injury or dislocation of the joint) processes. Patients will usually present with complaints of a clicking or locking sensation in the joint. In addition, they will present with pain in the hip or groin, stiffness and decreased range of motion. To diagnose a labral tear, physicians will utilize a combination of physical examination, imaging and diagnostic injection. X-rays and MRI arthrograms are typically utilized to diagnose a labral tear, while injections

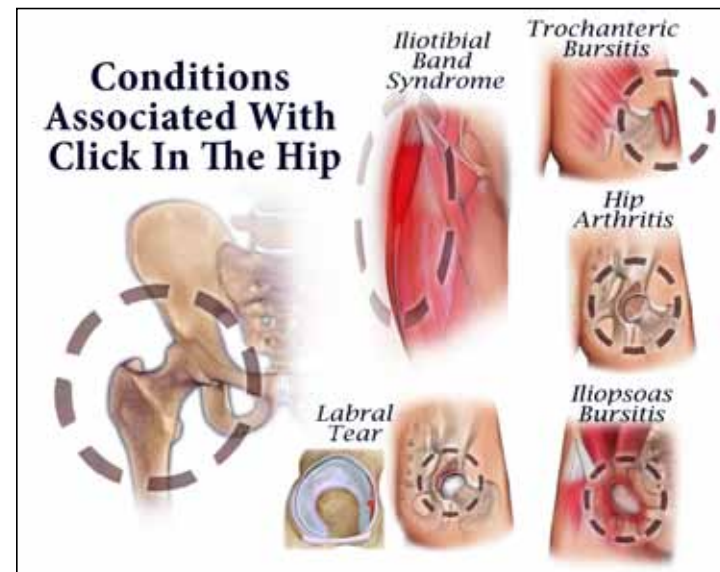
are also used to confirm the diagnosis. Treatment for a labral tear can range from conservative to surgical. Conservative treatment includes anti-inflammatory medications, physical therapy and injections. If conservative treatment fails, arthroscopic surgery may be needed to debride or repair the tear. Impingement of the hip can also be addressed.

A second common cause for a click in the hip deals with the tensor fascia lata, also known as the iliotibial band. The tensor fascia lata is composed of fibrous tissue extending from the lateral hip to the outside of the tibia. It is essential in providing both hip abduction and flexion. A click in the hip may be the result of the tensor fascia lata subluxing over the greater trochanter. This interaction may cause trochanteric bursitis if constantly reproduced.

Another cause for a click in the hip is iliopsoas bursitis and the iliopsoas tendon catching on a bony prominence of the pelvis when flexed. The iliopsoas is composed of the iliacus and psoas muscles. The iliopsoas, which lies in front of the hip joint, is essential in hip flexion. Between the tendon and the hip joint is the iliopsoas bursa. The iliopsoas bursa is a fluid-filled sac that reduces rubbing and friction of the bones and soft tissues that meet at the hip joint; this is the largest bursa in the body. When the bursa is overused or irritated, it becomes inflamed. This inflammation causes a sensation of clicking in the hip as well as pain and stiffness. To confirm iliopsoas bursitis, physicians will conduct a thorough physical examination and will confirm with MRI imaging.

A click in the hip also can be a symptom of arthritis in the hip joint. Arthritis results in the loss of cartilage between the head of the femur and acetabulum. Without adequate cartilage, there is bone-on-bone interaction that causes pain, tenderness and inflammation of the hip joint. Patients will present with stiffness (limited movement), clicking in the hip joint, pain worsening with activity and tenderness in the groin, hip, buttocks and sometimes into the knee. Physicians will utilize a combination of physical examination and X-ray imaging to identify loss of cartilage. Treatment for hip arthritis can be conservative or surgical. With severe arthritis, a hip replacement will be needed to remove and replace the arthritic joint.

Rarely, trochanteric bursitis also can cause a click in the hip. ■



Peroneal Tendon Subluxation

The peroneals are the two muscles and tendons that run behind the lateral malleolus along the outer edge of the lower leg. They are essential for plantar flexion (pointing downward) and eversion (pointing outward) of the foot. Peroneal tendon subluxation is a condition where the tendons move out of their anatomical positions and irregularly snap or pop back into place.

To adequately understand peroneal tendon subluxation, it is helpful to understand the involved anatomy. The peroneals are the primary muscles and tendons supporting the outer part of the ankle; they lie on the lateral part of the fibula and cross behind the lateral malleolus. The peroneal tendons pass through a groove behind the lateral malleolus and are housed within a sheath that forms a tunnel around the tendons.

The retinaculum is the band of ligaments on the surface of the sheath responsible for providing reinforcement.

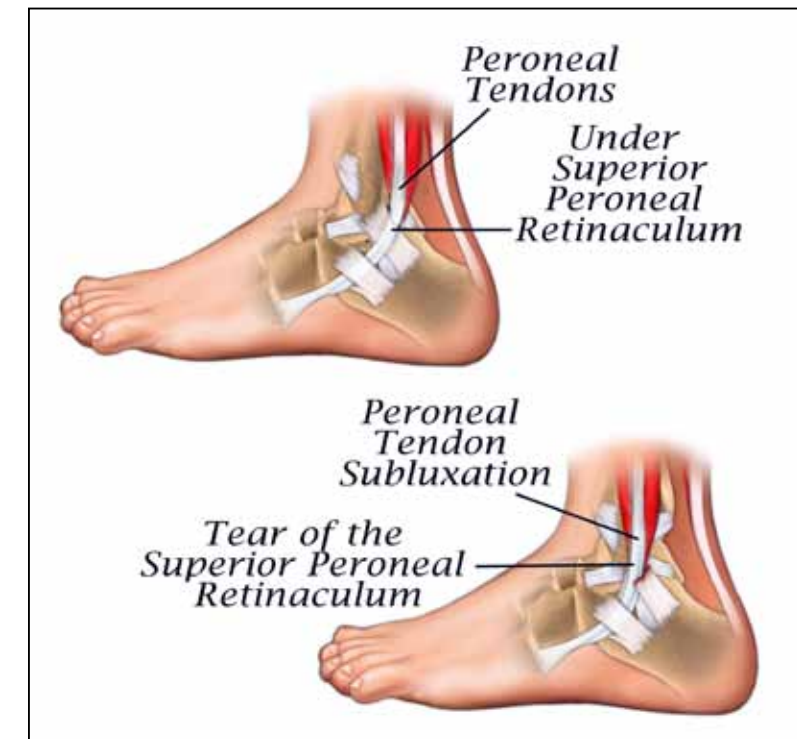
There are several conditions associated with peroneal tendon subluxation. Patients may have anatomical congenital differences predisposing them to peroneal tendon subluxation. These congenital anomalies include: a shallow groove, a loose retinaculum or a small or absent ridge. However, the most common cause for peroneal tendon subluxation is an ankle sprain and the resultant trauma. Physicians also should look for a retinaculum injury as it may cause peroneal tendon subluxation.

Patients with peroneal tendon subluxation will present with the following symptoms:

- Pain and tenderness along the tendons
- Snapping or popping sensation
- Ankle instability or weakness
- Swelling
- Noticeable tendon movement out of its anatomical position

To diagnose peroneal tendon subluxation, physicians utilize a combination of physical examination and imaging. During the physical examination, physicians check to see if the tendon moves out of place and relocates with movement of the ankle. X-rays or MRI imaging also may be taken to confirm the diagnosis and rule out other conditions. Stress views in dorsiflexion and eversion are essential for diagnosis.

Treatment for peroneal tendon subluxation can range from conservative to surgical. Conservative treatment involves immobilization, medications, physical therapy and bracing. However, conservative treatment may not be successful for patients who maintain active lifestyles. In these cases, surgery may be needed to treat the subluxing peroneal tendon, as consistent subluxation may lead to a rupture of the tendon. Surgical treatment may be utilized to repair the retinaculum, reconstruct the groove housing the peroneal tendons or provide bony blocks. ■



Aspiration of a Joint

Joint aspiration, also known as arthrocentesis, is a procedure where a sterile needle and syringe are used to drain fluid from the joint. In some cases, medication is injected following the fluid removal. Joint aspiration can be both diagnostic and therapeutic. It can be helpful in identifying etiology of inflammation, while therapeutic joint aspirations are helpful in providing pain relief, drainage of septic effusions or injection of medications.

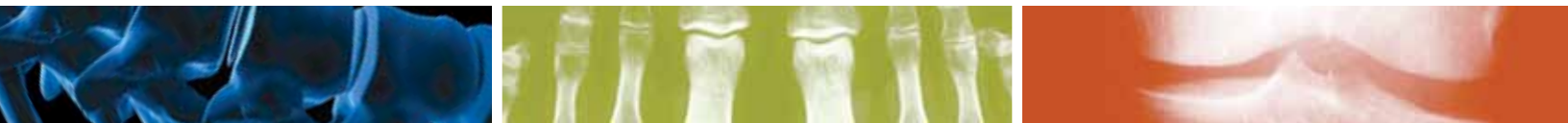Joints in the body are usually aspirated to identify infection and reduce swelling or are taken normally to obtain values.

In the case of infection, joint aspiration is done to identify whether or

not bacterial infection in the joint has caused inflammation. Here, a common infection is septic arthritis.

Aspiration of the joint also is done due to inflammation. Here, the goal is to remove fluid from the inflamed joint to reduce swelling and pain. As the fluid is removed, pressure decreases in the joint and improves movement.

Aspiration of the joint also may be done to test values in the body. Here, a joint may be aspirated to test for white cell count, protein, glucose and crystals. Gout will have needle-looking crystals that are negative and pseudo-gout are a rhomboid shape with crystals that are positive.

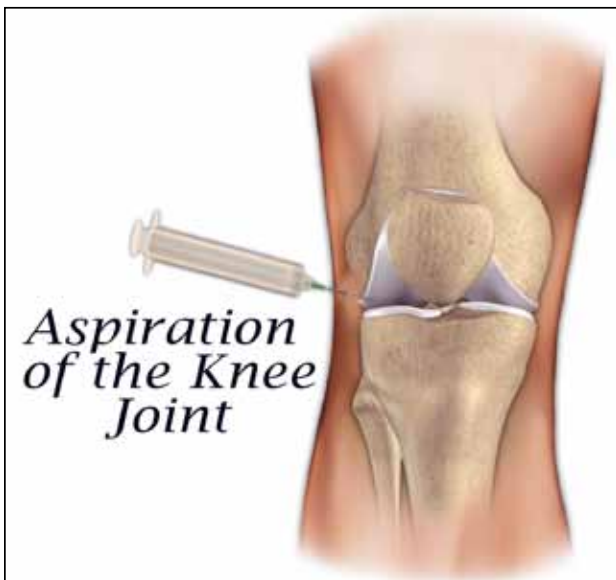


Aspiration of the joint continued from page 3.

The procedure begins by sterilizing the area with an iodine solution. In some cases, a local anesthesia is used either by injection or topical

freezing. A needle with a syringe is then inserted into the joint where fluid is removed. To combat certain conditions, a physician may also inject medication into the joint following fluid removal.

The physician usually looks at the color of the aspirated fluid. Is it a normal synovial-looking fluid or is it pus. Usually, the knee contains about 2-3 cc of fluid. If it contains more than 6-8 cc of fluid, it can cause quadriceps shutdown. White cell count is very important. The higher the count, the higher the chance of infection. You need only a 2500 white cell count for infection in a total joint. If aspiration of the knee reveals evidence of blood in the joint, there is a 75-80 percent chance of ACL or meniscal tear. ■



THE UNIVERSITY OF TOLEDO MEDICAL CENTER
**ORTHOPAEDIC
MONTHLY**

Editors:

Dr. Nabil Ebraheim,
department chair and
professor of orthopaedics and
Dave Kubacki, assistant to
the chairman

Neither Dr. Ebraheim nor Dave Kubacki have any relationships with industry to disclose.

**Department of
Orthopaedic Surgery**
3000 Arlington Ave
Toledo, Ohio 43614

For appointments,
call 419.383.3761.